

# Anal fistulas

---

New perspectives on treatment and pathogenesis



Robbert van Onkelen



# Anal fistulas: New perspectives on treatment and pathogenesis

Robbert Sebastiaan van Onkelen

Anal fistulas: New perspectives on treatment and pathogenesis

The work presented in this thesis was conducted at the Department of Immunology, and the Department of Surgery of the Erasmus Medical Center, Rotterdam, the Netherlands.

Printing of this thesis was financially supported by Erasmus University Rotterdam.

ISBN: 978-94-6169-782-0

Cover design: R.S. van Onkelen

Printing and lay-out: Optima Grafische Communicatie, Rotterdam, the Netherlands

© 2015 Robbert Sebastiaan van Onkelen. All rights reserved. None of the contents may be reproduced, stored, or transmitted in any form or by any means without prior written permission of the author, or when appropriate, the publisher of the published articles.

**Anal fistulas:  
New perspectives on treatment and pathogenesis**

**Anale fistels:  
Nieuwe inzichten in behandeling en pathogenese**

Proefschrift

ter verkrijging van de graad van doctor aan de  
Erasmus Universiteit Rotterdam,  
op gezag van de  
rector magnificus  
prof.dr. H.A.P. Pols  
en volgens besluit van het College voor Promoties.

De openbare verdediging zal plaatsvinden op  
dinsdag 24 november 2015 om 11.30 uur

door

Robbert Sebastiaan van Onkelen  
geboren te Alkmaar

## PROMOTIECOMMISSIE

Promotor        prof.dr. J.D. Laman

Overige leden    prof.dr. C.G.M.I. Baeten  
                      prof.dr. E.P. Prens  
                      prof.dr. C.J. van der Woude

Copromotor     dr. W.R. Schouten

## CONTENTS

Chapter 1	Introduction and outline of thesis	7
<b>Treatment</b>		
Chapter 2	Different characteristics of high and low transsphincteric fistulas	21
Chapter 3	Predictors of outcome after transanal advancement flap repair for high transsphincteric fistulas	31
Chapter 4	Is it possible to improve the outcome of transanal advancement flap repair for high transsphincteric fistulas by additional ligation of the intersphincteric fistula tract?	45
Chapter 5	Ligation of the intersphincteric fistula tract in low transsphincteric fistulas: A new technique to avoid fistulotomy	55
Chapter 6	Treatment of anal fistulas with high intersphincteric extension	67
<b>Pathogenesis</b>		
Chapter 7	Identification of epithelialization in high transsphincteric fistulas	79
Chapter 8	Assessment of microbiota and peptidoglycan in perianal fistulas	89
Chapter 9	Pro-inflammatory cytokines in anal fistulas	103
<b>Appendices</b>		
Chapter 10	Summary and general discussion	115
Chapter 11	Summary in Dutch (Nederlandse samenvatting)	127
Chapter 12	Acknowledgments (Dankwoord)	137
	About the author	143
	List of publications	145
	PhD portfolio	147





Chapter 1

# **Introduction and outline of thesis**



## GENERAL INTRODUCTION

Fistula is the Latin word for a reed, pipe or flute. In medicine a fistula is defined as an abnormal communication between two epithelium lined surfaces. Anal fistulas are abnormal communications between the anal canal and the perianal skin or perineum. They are associated with considerable discomfort and morbidity and patients will frequently have cyclic periods in which the external fistula opening temporarily closes causing pain and swelling until the external fistula opening opens again leading to release of purulent material or blood. The incidence of anal fistulas varies between 0.86 and 2.32 per 10.000/year,<sup>1,2</sup> there is a male predominance with ratios varying from 2:1 to 5:1<sup>1,3-5</sup> and most patients are between 30 and 50 years old.<sup>1</sup> Overall anal fistulas are considered to be a discomforting disease that require adequate treatment.

## ANATOMY

A thorough understanding of the anorectal anatomy is essential for classification and treatment of anal fistulas. The rectum begins at the level of the promontorium and in general follows along the curvature of the sacrum and coccyx for its entire length. As the rectum passes through the pelvic diaphragm at the level of the anorectal ring it becomes the anal canal and extends for 2 to 5 centimeters in length. The upper two third of the anal canal is lined by simple columnar epithelium and the lower one third of the anal canal is lined by stratified squamous epithelium. The dentate line divides both and is defined by the anal columns. At this level the ducts of the anal glands flow into the anal crypts. More than one anal gland may open into the same crypt and 30 to 50% of the anal glands branch out into the intersphincteric space. The number of anal glands is higher in men than women. Immunohistochemical staining methods have shown presence of mucous secreting cells and intraluminal secretions in these glands.<sup>6</sup> However, it remains controversial whether these glands have an active secretory function.

The anal canal is surrounded by the internal and external anal sphincter muscle and they are considered to be essential for fecal continence. Both anal sphincter are equally thick between sexes. However, in women the anterior part of the external anal sphincter is shorter. The internal anal sphincter consists of smooth muscle and is innervated by the autonomic nervous system while the external anal sphincter consists of striated skeletal muscle and has somatic innervation. At the upper level the external anal sphincter becomes continuous with the puborectal muscle, which forms a sling behind the anal canal and is attached to the pubic bone. The puborectal muscle is part of the levator ani muscle, a broad thin muscle that forms the pelvic floor. Both the

high-pressure zone in the anal canal and the angulation between the rectum and anal canal, which is a result of the tonic contraction of the puborectal muscle, contribute to fecal continence. Both anal sphincters are responsible for the anal high-pressure zone at rest, however the internal anal sphincter supplies the largest contribution to this anal resting pressure.

## ETIOLOGY AND PATHOGENESIS

Anal fistulas are the result of an infection. Anorectal infections can be classified as specific or nonspecific. Specific causes for anal fistulas involve identifiable primary diseases, such as Crohn's disease, or specific mechanism, such as iatrogenic or obstetric trauma. These specific causes are not the focus of this thesis. The way nonspecific anorectal infections cause anal fistulas is described by the cryptoglandular hypothesis.<sup>7-12</sup> Although it is impossible to prove this hypothesis, it is generally accepted by surgeons. The cryptoglandular hypothesis states that anal fistulas arise from anal glands. Anal glands flow into the anal crypts and drain into the anal canal. If these glands become blocked, stasis occurs and infection develops. Because 30 to 50% of the anal glands extend into the intersphincteric space, infection can pass the internal anal sphincter that serves as a barrier against contamination. Less well known is that in 1967 Goligher and colleagues challenged the cryptoglandular hypothesis.<sup>13</sup> In a series of 29 patients with an acute perianal abscess, only five showed communication with the crypt region, supporting the argument that in about two-thirds of the anorectal infections the cryptoglandular etiology does not apply. Studies on the etiology of anal fistulas are rare and therefore more studies are needed to understand it completely.

Anorectal infection can follow two routes, 1. Downward or upward between the internal and external anal sphincter; 2. Through the external anal sphincter by a transsphincteric or extrasphincteric tract. From these two routes four types of anal abscesses may develop, 1. Perianal; 2. Intersphincteric; 3. Ischioanal; 4. Supralelevator. After incision and drainage of an anal abscess, an anal fistula remains in about half of the patients.<sup>14</sup>

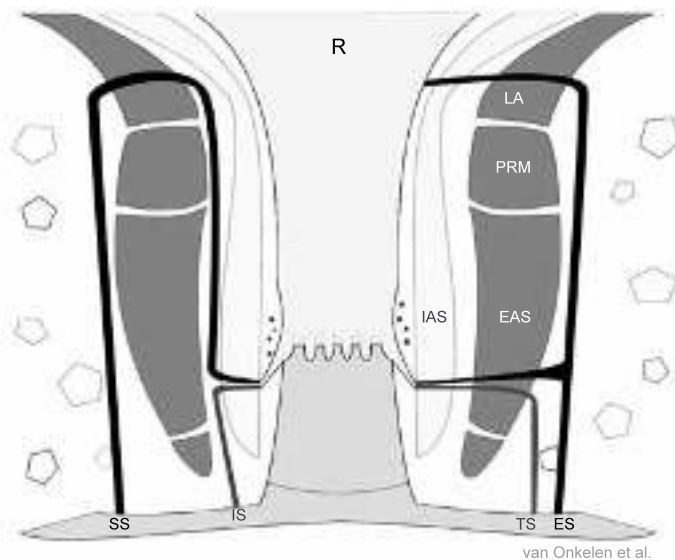
Although many anal fistulas are considered simple and are easy to treat, others can be complex and treatment is challenging with a substantial risk of recurrence. It is not clear which factors contribute to the persistence of anal fistulas after surgery. The microbiology of anal abscesses has been well described.<sup>15-17</sup> The bacteria cultured from perianal abscesses include bowel-derived organisms, skin-derived-organisms, or a combination of both. According to some authors, bowel-derived organisms are associated with subsequent occurrence of an anal fistula.<sup>15,16</sup> However, this finding could not be confirmed by others.<sup>18</sup> Only a few studies have been conducted to assess

the microbiology of cryptoglandular anal fistulas.<sup>19-21</sup> These studies showed that the microbiota in anal fistulas is similar to the microbiota of anal abscesses. However, cultures yielded much smaller numbers of organisms in comparison with pus obtained from anal abscesses. Furthermore, they were not able to detect pathogenic organisms.

## CLASSIFICATION

The general accepted classification of anal fistulas is based on the course of the fistula tract in relation of the anal sphincter muscles.<sup>22</sup> This classification is essential for the choice of treatment. Four main types of fistulas have been identified: intersphincteric, transsphincteric, suprasphincteric and extrasphincteric (Figure 1). Additionally, a distinction is made between high and low transsphincteric fistulas.

1. Intersphincteric fistulas extend downward in the intersphincteric space to the perianal skin.
- 2.1. Low transsphincteric fistulas pass through the lower third of the external anal sphincter before extending downward to the perianal skin.
- 2.2. High transsphincteric fistulas pass through the upper or middle third of the external anal sphincter before extending downward to the perianal skin.



**Figure 1.** Location of the four main anal fistula types

The fistula tracts are colored black. IS = Intersphincteric fistula; TS = Transsphincteric fistula; SS = Supra-sphincteric fistula; ES = Extrasphincteric fistula; R = Rectum; PRM = Puborectal muscle; EAS = External anal sphincter; IAS = Internal anal sphincter; LA = Levator ani muscle.

3. Suprasphincteric fistulas extend in the intersphincteric space to a point above the puborectal muscle and transfer through the pelvic floor before extending downward through the ischiorectal space to the perianal skin.
4. Extrasphincteric fistulas pass through the external anal sphincter and branch out into two tracts, one tract extends upward before passing through the pelvic floor and ending in the rectum and the other tract extends downward to the perianal skin.

## SURGICAL TREATMENTS

Hippocrates was probably the first to describe several treatments for anal fistulas and some of his techniques, such as a seton, are still used today.<sup>23</sup> Many anal fistulas are considered simple and are easy to treat. However, treatment of more complex anal fistulas is challenging. The main objective in treatment is fistula healing with minimal fecal continence disturbances. Intersphincteric fistulas and low transsphincteric fistulas are considered simple anal fistulas and require division of only a small portion of the anal sphincter muscle(s) by fistulotomy (lay-open) or fistulectomy (excision). In general, these surgical procedures lead only to minimal fecal continence disturbances. Complex anal fistulas require division of more anal sphincter muscle and therefore lead to more fecal continence disturbances if fistulotomy or fistulectomy are performed. Hence, alternative sphincter saving treatments are developed, such as transanal advancement flap repair (TAFR) and ligation of the intersphincteric fistula tract (LIFT). The choice of treatment will depend on the classification, location of the internal fistula opening and presence of associated abscesses.

### Fistulotomy

The classical treatment of anal fistulas is to surgically lay-open the fistula (fistulotomy). Although fistulotomy seems to be the most effective treatment for anal fistulas, a major drawback of this procedure is the need for anal sphincter division with the risk of subsequent fecal continence disturbances. Therefore, fistulotomy is only accepted for anal fistulas that require division of a small proportion of the anal sphincters, such as intersphincteric and low transsphincteric anal fistulas. For low transsphincteric fistulas it can be debated if fistulotomy is appropriate. Although the exact incidence of diminished fecal continence after fistulotomy for low transsphincteric fistulas cannot be assessed, data obtained from studies conducted so far suggest that fecal continence disturbances after surgical treatment of low fistulas are more common than previously thought (Table 1).

**Table 1.** Impairment of fecal continence after fistulotomy for low anal fistula

Author	Year	N	Postoperative incontinence*		
			Minor (%)	Major (%)	Minor and/or Major (%)
Garcia-Aguilar et al. <sup>42</sup>	1996	177	-	-	39
Mylonakis et al. <sup>43</sup>	2001	65	9	0	
Westerterp et al. <sup>44</sup>	2003	18	44	0	
Chang and Lin. <sup>45</sup>	2003	45	-	-	38
van der Hagen et al. <sup>46</sup>	2006	62	5	0	
Toyonaga et al. <sup>47</sup>	2007	148	-	-	20
Van Koperen et al. <sup>48</sup>	2008	63	41	5	-
Bokhari and Lindsey. <sup>49</sup>	2010	53	11	5	-
Atkin et al. <sup>50</sup>	2011	51	23	2	-

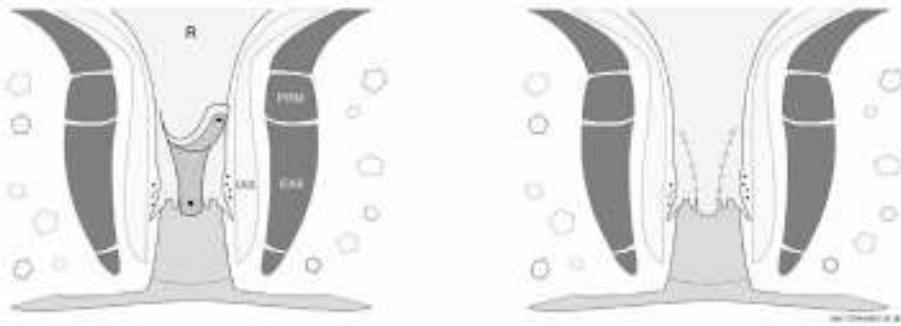\*Minor incontinence is incontinence for gas and/or soiling. Major incontinence is incontinence for solid and/or liquid stool.

### Transanal advancement flap repair

Fistulotomy is not appropriate for anal fistula types that require division of a large proportion of the anal sphincters, such as high transsphincteric anal fistulas. For these types of anal fistula a sphincter preserving treatment is more appropriate.

In 1902, Noble was the first to describe a sphincter preserving technique for rectovaginal fistulas, transanal advancement flap repair (TAFR).<sup>24</sup> Ten years later Elting applied this technique in patients with anal fistulas.<sup>25</sup> The purpose of the flap is to sever communication between the anal canal and fistula tract after the diseased internal opening is removed. In 1948, Laird described a modification by adding fibres of the internal anal sphincter muscle to the flap and this type of flap repair is currently considered by many surgeons to be the golden standard for sphincter preserving treatment of anal fistulas.<sup>26</sup> The healing rate after TAFR varies between 60 and 70%.<sup>27-31</sup> Although anal sphincters are not divided, the rates of fecal continence disturbances after TAFR are up to 35%.<sup>31</sup> While creating the flap, fibres of the internal anal sphincter are used to provide strength for the flap. Theoretically, this can affect fecal continence.

TAFR is performed with the patient in prone jack-knife position and the internal opening of the fistula exposed using a retractor. The internal opening is enlarged and the remaining crypt-bearing tissue is excised. A small rim of the anodermis, below the internal opening, is excised to create a neodentate line. The defect in the internal anal sphincter is closed. A flap consisting of mucosa, submucosa and some of the most superficial fibres of the internal anal sphincter, is raised from the level of the dentate line and mobilized over a distance of four to six centimetres proximally. The flap is advanced and sutured to the neodentate line. Subsequently, the external opening is



**Figure 2.** Steps involved in transanal advancement flap repair

A flap consisting of mucosa, sub mucosa and some of the most superficial fibres of the internal anal sphincter, is raised from the level of the dentate line and mobilized over the internal fistula opening (black dot). The flap is advanced and sutured to the neodentate line with absorbable sutures (red). R = Rectum; PRM = Puborectal muscle; EAS = External anal sphincter; IAS = Internal anal sphincter.

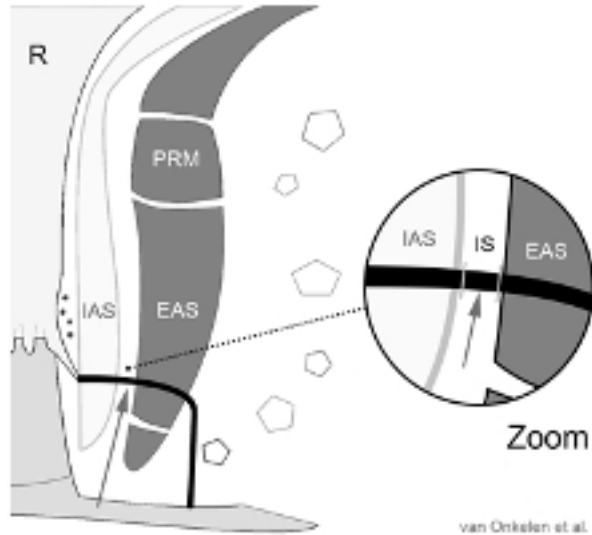
enlarged and the fistula tract is excised as far as possible until the outer border of the external anal sphincter (Figure 2).

### Ligation of the intersphincteric fistula tract

In 2009, ligation of the intersphincteric fistula tract (LIFT) has been introduced as a promising sphincter preserving alternative for TAFR.<sup>32</sup> The LIFT technique is based on an original concept regarding eradication of the fistulous disease at its intersphincteric origin whilst preserving both anal sphincters. Rojanasakul was the first to describe this new technique. He observed primary fistula healing in 94% of his patients.<sup>32</sup> Other reports from Asia also revealed high healing rates, exceeding those obtained with the current sphincter preserving techniques.<sup>33,34</sup> However, recent reports from the USA and Australia showed healing rates comparable with those after TAFR.<sup>35-37</sup> No fecal continence disturbances are described after LIFT. Over the last few years, this new technique has generated considerable interest and LIFT is now perhaps as often applied as TAFR.

LIFT is performed with the patient in prone jack-knife position and the internal opening of the fistula exposed using a retractor. Then a probe is introduced into the fistula tract. A curvilinear incision is made, just outside the intersphincteric groove. Dissection is continued in the intersphincteric space until the fistula tract is encountered. After isolation of the fistula tract the probe is removed and the tract is ligated with sutures close to the internal and external anal sphincter. Then the tract is transected between the two ligation points. Some surgeons do not transect but only ligate the fistula tract. Finally, the wound is loosely closed with sutures. Subsequently, the external opening is





**Figure 3.** Steps involved in ligation of the intersphincteric fistula tract  
Just outside the intersphincteric groove a curvilinear incision is made. Dissection is continued in the intersphincteric space until the fistula tract (black line) is encountered (large arrow). After isolation of the fistula tract in the intersphincteric space, the tract is ligated with absorbable sutures and transected between the two ligation points (small arrow). R = Rectum; PRM = Puborectal muscle; EAS = External anal sphincter; IAS = Internal anal sphincter; IS = Intersphincteric space.

enlarged and the fistula tract is excised as far as possible until the outer border of the external anal sphincter (Figure 3).

## OUTLINE THESIS

The general objective of the studies described in this thesis is to evaluate treatments for anal fistulas and to gain a better understanding of the pathogenesis of anal fistulas.

Chapter 2 presents an observational study on the different characteristics of high and low transsphincteric anal fistulas. Transsphincteric fistulas are classified as high or low. High transsphincteric fistulas pass through the upper or middle third of the external anal sphincter, whereas low transsphincteric fistulas traverse the lower third of the external anal sphincter. This classification has been used for selecting the optimal treatment and for supporting the choice between non-sphincter preserving and sphincter preserving techniques. Although the distinction between high and low transsphincteric anal fistulas is commonly practiced, it is unknown whether these fistulas have similar characteristics.

Chapter 3 describes a retrospective study on predictors of outcome after transanal advancement flap repair for high transsphincteric fistulas. It has been reported that smoking, obesity and previous attempts at repair adversely affect the outcome of transanal advancement flap repair.<sup>29,31,38,39</sup> Because these findings could not be confirmed by other studies, it is still unclear whether these and other factors have an impact on the outcome.

Chapter 4 presents a prospective study on the effect of an additional ligation of the fistula tract on the outcome of transanal advancement flap repair for high transsphincteric anal fistulas. Transanal advancement flap repair is successful in two of every three patients with a high transsphincteric anal fistula.<sup>27-31</sup> It has been suggested that ongoing disease in the remaining fistula tract contributes to failure.

Chapter 5 addresses a prospective study on ligation of the intersphincteric fistula tract for low transsphincteric anal fistulas. Ligation of the intersphincteric fistula tract is a promising sphincter preserving technique.<sup>32-34</sup> To date fistulotomy is still the treatment of choice for low transsphincteric anal fistulas. However, studies suggest that fecal continence disturbances are more common than thought after fistulotomy.

Chapter 6 describes a retrospective study on transanal advancement flap repair combined with drainage of associated abscesses for high intersphincteric fistulas. Intersphincteric fistulas with a high upward extension, up to or above the level of the puborectal muscle, in the intersphincteric plane are rare and difficult to treat.

Chapter 7 presents a study on the prevalence of epithelialization of the fistula tract and the effect of epithelialization on the outcome of fistula surgery. It has been suggested that epithelialization of the fistula tract contributes to the failure of treatment.<sup>40,41</sup>

Chapter 8 describes a study on the microbiota of anal fistulas by means of conventional microbiological culture and 16S rRNA gene sequencing and immunohistochemistry. Transanal advancement flap repair has been advocated as the treatment of choice for high transsphincteric anal fistulas, but fails in one of every three patients.<sup>27-31</sup> Persistence of anal fistulas might be the result of ongoing disease in the remaining fistula tract.

Chapter 9 addresses a study on cytokines in anal fistulas by means of advanced immuno-enzyme staining methods. Sphincter preserving procedures for the treatment of transsphincteric fistulas fail in one out of every three patients.<sup>27-31</sup> It has been suggested that failure is due to ongoing disease in the remaining fistula tract. Cytokines play an important role in inflammation. At present biologicals targeting cytokines are available. Therefore, detection and identification of cytokines in anal fistulas can have implications for future treatment modalities.

## REFERENCES

1. Saino P. Fistula-in-ano in a defined population. Incidence and epidemiological aspects. *Ann Chir Gynaecol.* 1984;73:219-224.
2. Zanotti C, Martinez-Puente C, Pascual I, et al. An assessment of the incidence of fistula-in-ano in four countries of the European Union. *Int J Colorectal Dis.* 2007;22:1459-1462.
3. Marks CG, Ritchie JK. Anal fistulas at St Mark's Hospital. *Br J Surg.* 1977;64:84-91.
4. Shouler PJ, Grimley RP, Keighley MR, et al. Fistula-in-ano is usually simple to manage surgically. *Int J Colorectal Dis.* 1986;1:113-115.
5. Vasilevsky CA, Gordon PH. Results of treatment of fistula-in-ano. *Dis Colon Rectum.* 1985;28:225-231.
6. Seow-Choen F, Ho JM. Histoanatomy of anal glands. *Dis Colon Rectum.* 1994;37:1215-1218.
7. Parks AG. Pathogenesis and treatment of fistula in ano. *BMJ.* 1961;1:463-466.
8. Hermann G, Desfosses L. Sur la muqueuse de la region cloacole de rectum. *Compts Rend Acad Sci.* 1880;90:1301-1302.
9. Tucker CC, Hellwing CA. Histopathology of anal glands. *Surg Gynecol Obstet.* 1933;58:145-149.
10. Hill MR, Shryock EH, Rebell G. Role of anal glands in the pathogenesis of anorectal disease. *JAMA.* 1943;121:742-746.
11. Kratzer G. Anal ducts and their clinical significance. *Am J Surg.* 1950;79:32-39.
12. Eisenhammer S. The internal anal sphincter and the anorectal abscess. *Surg Gynecol Obstet.* 1956;103:501-506.
13. Goligher JC, Ellis M, Pissidis G. A critique of the anal glandular infection in the aetiology and treatment of idiopathic anorectal abscesses and fistulae. *Br J Surg.* 1967;54:977-983.
14. Schouten WR, van Vroonhoven TJ. Treatment of anorectal abscess with or without primary fistulectomy. *Dis Colon Rectum.* 1911;34:60-63.
15. Whitehead SM, Leach RD, Eykyn SJ, et al. The aetiology of perirectal sepsis. *Br J Surg.* 1982;69:166-168.
16. Grace RH, Harper IA, Thompson RG. Anorectal sepsis: microbiology in relation to fistula-in-ano. *Br J Surg.* 1982;69:401-403.
17. Toyonaga T, et al. Microbiological analysis and endoanal ultrasonography for diagnosis of anal fistula in acute anorectal sepsis. *Int J Colorectal Dis.* 2007;22:209-213.
18. Lunniss PJ, Phillips RKS. Surgical assessment of acute anorectal sepsis is a better predictor of fistula than microbiological analysis. *Br J Surg.* 1994;81:368-369.
19. de San Ildefonso Pereira A, Maruri Chimeno I, Facal Alvarez C, et al. Bacteriology of anal fistulae. *Rev Esp Enferm Dig.* 2002;94:533-536.
20. Lunniss PJ, Faris B, Rees HC, et al. Histological and microbiological assessment of the role of microorganisms in chronic anal fistula. *Br J Surg.* 1993;80:1072.
21. Seow-Choen F, Hay AJ, Heard S, et al. Bacteriology of anal fistulae. *Br J Surg.* 1992;79:27-28.
22. Parks AG, Gordon PH, Hardcastle JD. A classification of fistula-in-ano. *Br J Surg.* 1976;63:1-12.
23. Corman ML. Classic articles in colon and rectal surgery. Hippocrates: on fistulae. *Dis Colon Rectum.* 1980;23:56-59.
24. Noble GH. A new operation for complete laceration of the perineum designed for the purpose of eliminating danger of infection from the rectum. *Trans Am Gynecol Soc.* 1902;27:357-363.
25. Elting AW. The treatment of fistula in ano with special reference to the Whitehead operation. *Ann Surg.* 1912;56:744-752.

26. Laird DR. Procedures used in the treatment of complicated fistulas. *Am J Surg*. 1948;76:701-708.
27. Lunniss PJ, Kamm MA, Phillips RK. Factors affecting continence after surgery for anal fistula. *Br J Surg*. 1994;81:1382-1385.
28. Mitalas LE, Gosselink MP, Oom DM, et al. Required length of follow-up after transanal advancement flap repair of high transsphincteric fistulas. *Colorectal Dis*. 2008;11:726-728.
29. Zimmerman DD, Delemarre JB, Gosselink MP, et al. Smoking affects the outcome of transanal mucosal advancement flap repair of transsphincteric fistulas. *Br J Surg*. 2003;90:351-354.
30. Mizrahi N, Wexner SD, Zmora O, et al. Endorectal advancement flap: are there predictors of failure? *Dis Colon Rectum*. 2002;45:1616-1621.
31. Schouten WR, Zimmerman DD, Briel JW. Transanal advancement flap repair of transsphincteric fistulas. *Dis Colon Rectum*. 1999;42:1419-1422.
32. Rojanasakul A. LIFT procedure: a simplified technique for fistula-in-ano. *Tech Coloproctol*. 2009;13:237-240.
33. Shanwani A, Azmi M, Amri N. The ligation of intersphincteric fistula tract (LIFT) for fistula-in-ano: sphincter saving technique. *Dis Colon Rectum*. 2010;53:39-42.
34. Tan K, Tan IJ, Lim FS, et al. The anatomy of failures following the ligation of intersphincteric fistula tract technique for anal fistula: a review of 93 patients over 4 years. *Dis Colon Rectum*. 2011;54:1368-1372.
35. Bleier H, Moloo H, Goldberg S. Ligation of the intersphincteric fistula tract (LIFT): an effective new technique for complex fistulas. *Dis Colon Rectum*. 2010;53:43-46.
36. Aboulian A, Kaji AH, Kumar RR. Early results of ligation of the intersphincteric fistula tract for fistula-in-ano. *Dis Colon Rectum*. 2011;54:289-292.
37. Ooi K, Skinner I, Croxford M, et al. Managing fistula-in-ano with ligation of the intersphincteric fistula tract procedure: the Western Hospital experience. *Colorectal Dis*. 2011;14:599-603.
38. Ellis CN, Clark S. Effect of tobacco smoking on advancement flap repair of complex anal fistulas. *Dis Colon Rectum*. 2007;50:459-463.
39. Schwandner O. Obesity is a negative predictor of success after surgery for complex anal fistula. *BMC Gastroenterology*. 2011;11:61.
40. Lunniss PJ, Sheffield JP, Talbot IC, et al. Persistence of idiopathic anal fistula may be related to epithelialization. *Br J Surg*. 1995;82:32-33.
41. Van Koperen PJ, Ten Kate FJW, Bemelman WA, et al. Histological identification of epithelium in perianal fistulae: a prospective study. *Colorectal Dis*. 2010;12:891-895.
42. Garcia-Aguilar J, Belmonte C, Wong WD, et al. Anal fistula surgery. Factors associated with recurrence and incontinence. *Dis Colon Rectum*. 1996;39:723-729.
43. Mylonakis E, Katsios C, Godevenos D, et al. Quality of life of patients after surgical treatment of anal fistula; the role of anal manometry. *Colorectal Dis*. 2001;3:417-421.
44. Westerterp M, Volkers NA, Poolman RW, et al. Anal fistulotomy between Skylla and Charybdis. *Colorectal Dis*. 2003;5:549-551.
45. Chang SC, Lin JK. Change in anal continence after surgery for intersphincteric anal fistula: a functional and manometric study. *Int J Colorectal Dis*. 2003;18:111-115.
46. Van der Hagen SJ, Baeten CG, Soeters PB, et al. Long-term outcome following mucosal advancement flap for high perianal fistulas and fistulotomy for low perianal fistulas: recurrent perianal fistulas: failure of treatment or recurrent patient disease? *Int J Colorectal Dis*. 2006;21:784-790.

47. Toyonaga T, Matsushima M, Kiriu T, et al. Factors affecting continence after fistulotomy for intersphincteric fistula-in-ano. *Int J Colorectal Dis.* 2007;22:1071-1075.
48. Van Koperen PJ, Wind J, Bemelman WA, et al. Long-term functional outcome and risk factors for recurrence after surgical treatment for low and high perianal fistulas of cryptoglandular origin. *Dis Colon Rectum.* 2008;51:1475-1481.
49. Bokhari S, Lindsey I. Incontinence following sphincter division for treatment of anal fistula. *Colorectal Dis.* 2009;12:135-139.
50. Atkin GK, Martins J, Tozer P, et al. For many high anal fistulas, lay open is still a good option. *Tech Coloproctol.* 2011;15:143-150.



## Chapter 2

# **Different characteristics of high and low transsphincteric fistulae**

R.S. van Onkelen, M.P. Gosselink, J. van Rosmalen, S. Thijsse and W.R. Schouten

*Colorectal Disease* 2014;16:403-492

## ABSTRACT

### Background

Transsphincteric fistulas are classified as high or low. Aim of this observational study was to determine whether high and low transsphincteric fistulas have different characteristics or not.

### Method

A consecutive series of 300 patients with a transsphincteric fistula of cryptoglandular origin were studied. Two hundred patients with a high transsphincteric fistula underwent transanal advancement flap repair and 100 patients with a low transsphincteric fistula underwent fistulotomy or ligation of the intersphincteric fistula tract at the Division of Colon and Rectal Surgery, Erasmus MC, Rotterdam. Various patient and fistula characteristics were assessed. Data were analysed by means of logistic regression.

### Results

Low transsphincteric fistulas occurred more frequently in females (43% vs. 30% in high transsphincteric fistulas;  $P<0.05$ ). The internal opening of these fistulas was predominantly located anteriorly (76% vs. 18% in high transsphincteric fistulas;  $P<0.001$ ). Mean age at surgery was lower in patients with a low transsphincteric fistula (42 vs. 47 years;  $P<0.001$ ). In almost none of these patients an associated abscess was observed (4% vs. 54% in high transsphincteric fistulas;  $P<0.001$ ). In multivariate analysis, the differences between high and low transsphincteric fistulas regarding location of their internal opening and the presence of associated abscesses remained significant ( $P<0.001$ ).

### Conclusion

Although not significant in multivariate analysis, low transsphincteric fistulas occur more frequently at younger age and more often in female patients. Furthermore, these fistulas are predominantly located anteriorly and are rarely associated with an abscess. This was significant in univariate and multivariate analysis.



## INTRODUCTION

Classification of anal fistulas is based on the course of the fistula tract in relation to the anal sphincters. Four main types of fistulas have been identified: intersphincteric, transsphincteric, suprasphincteric and extrasphincteric.<sup>1,2</sup> Transsphincteric fistulas are classified as high or low. High transsphincteric fistulas pass through the upper or middle third of the external anal sphincter, whereas low transsphincteric fistulas traverse the lower third of the external anal sphincter. This classification has been used for selecting the optimal treatment and for supporting the choice between non-sphincter preserving procedures, such as fistulotomy, and sphincter preserving techniques, such as transanal advancement flap repair and ligation of the intersphincteric fistula tract.<sup>3-6</sup> Although the distinction between high and low transsphincteric fistulas has been widely accepted, it is unknown whether these fistulas have different characteristics or not. The aim of this observational study was to assess any differences in patient and fistula characteristics between high and low transsphincteric fistulas.

## METHOD

A consecutive series of 300 patients with a transsphincteric fistula of cryptoglandular origin were studied. This series consisted of the last 200 patients with a high transsphincteric fistula who underwent transanal advancement flap repair (TAFR) and the last 100 patients with a low transsphincteric fistula who underwent fistulotomy or ligation of the intersphincteric fistula tract, in the time period preceding May 2013. For all patients this was their first surgical intervention at the Division of Colon and Rectal Surgery, Erasmus MC, Rotterdam. Prior to the procedure all patients underwent endoanal magnetic resonance imaging (EA MRI) to visualize the course of the fistula tract and to determine the presence and location of associated abscesses. Patients with a rectovaginal fistula or a fistula due to Crohn's disease were excluded from this study. All patients provided informed consent meeting the standards set by the hospital's Institutional Review Board.

### Assessment of characteristics

The following characteristics of high and low transsphincteric fistulas were assessed: age, sex, presence of associated abscesses, location of internal fistula opening, body mass index, smoking, alcohol consumption, diabetes mellitus and hypertension. Presence of associated abscesses and location of the internal opening was assessed by EA MRI and careful examination during the procedure. Location of the internal fistula opening was described as anterior or posterior. Body mass index was calculated by

dividing the patient's body mass (kilograms) by the square of their height (meters). In accordance to the World Health Organisation overweight was defined as a body mass index between 25 and 30 and obesity was defined as a body mass index of 30 or more. Smoking was classified as excessive if the patient smoked 10 or more cigarettes a day. Diabetes mellitus and hypertension were included as characteristics if the patient used blood glucose-lowering medication or antihypertensive drugs respectively. These aspects and other details regarding lifestyle such as smoking and alcohol consumption were obtained from the preoperative checklists. Further information was obtained from medical records by one author who had not participated in the surgical procedure.

### Statistical analysis

Continuous data are presented as mean values with standard deviation. Categorical data are presented as frequencies or percentages. Continuous data were tested with the Mann-Whitney *U* test and categorical data were tested with the Fisher's exact test. Multivariate logistic regression was performed to adjust for all variables in the model. Bonferroni correction was used to adjust the *P*-values for multiple testing. The results from multivariate logistic regression were presented with and without Bonferroni correction. The sample size satisfies the rule of thumb of 10 cases per variable, which suggests that the sample size is adequate. Based on our extensive clinical experience in treatment of anal fistulas we expected significant differences in characteristics between patients with a high transsphincteric fistula and patients with a low transsphincteric fistula. The *P*-value threshold used for significance was 0.05 and all tests were two-sided. Data were analysed by use of SPSS-IBM® software version 20.0 for Windows® (SPSS, Chicago, IL).

## RESULTS

Twelve patient and fistula characteristics were assessed. Many, such as body mass index, overweight, obesity, smoking, excessive smoking, alcohol consumption, diabetes mellitus and hypertension, did not differ significantly between high and low transsphincteric fistulas. In univariate analysis, a significant difference between high and low transsphincteric fistulas was observed for mean age at surgery, gender, location of the internal fistula opening and presence of associated abscesses. In patients with a high transsphincteric fistula, mean age at surgery was higher than in patients with a low transsphincteric fistula (47 vs. 42 years;  $P < 0.001$ ). Compared to high transsphincteric fistulas, low transsphincteric fistulas occurred more frequently in female patients (43.0% vs. 29.5%;  $P = 0.028$ ). The male to female ratio was 1.3 for low

**Table 1.** Univariate analysis of patient and fistula characteristics of high and low transsphincteric fistulas (n = 300)

Characteristic	High transsphincteric fistulas (n = 200)	Low transsphincteric fistulas (n = 100)	P-value*
Age (years)	47 ± 10.3	42 ± 11.8	<0.001**
Sex			
Male	141 (70.5)	57 (57.0)	0.028
Female	59 (29.5)	43 (43.0)	
Associated abscesses	108 (54.0)	4 (4.0)	<0.001
Location of the internal opening			
Anterior	35 (17.5)	76 (76.0)	<0.001
Posterior	165 (82.5)	24 (24.0)	
BMI (kg/m <sup>2</sup> )	27.1 ± 4.3	26.8 ± 4.2	0.452**
Overweight, BMI 25-30	137 (68.5)	60 (60.0)	0.347
Obesity, BMI ≥ 30	49 (24.5)	21 (21.0)	0.622
Smoking	77 (38.5)	33 (33.0)	0.440
Excessive smoking	61 (30.5)	24 (24.0)	0.335
Alcohol consumption	117 (58.5)	51 (51.0)	0.307
Diabetes mellitus	8 (4.0)	4 (4.0)	1.000
Hypertension	23 (11.5)	12 (12.0)	1.000

Categorical variables are presented as numbers (%). Continuous values are expressed as mean ± SD. The baseline category for each variable is the presence of the characteristic, or stated otherwise in the table. BMI, body mass index. \*Fisher's exact test unless indicated otherwise; \*\*Mann-Whitney *U* test.

**Table 2.** Multivariate analysis of patient and fistula characteristics of high and low transsphincteric fistulas (n = 300)

Characteristic	OR	95% Confidence interval	P-value*
Age (years)	1.0	0.96 - 1.02	0.529
Sex (male)	1.1	0.53 - 2.22	0.835
Associated abscesses	0.1	0.03 - 0.27	<0.001**
Location of the internal opening (anterior)	8.5	4.17 - 17.48	<0.001**
BMI (kg/m <sup>2</sup> )	0.9	0.84 - 1.00	0.037
Smoking	1.1	0.55 - 2.37	0.716
Alcohol consumption	0.8	0.37 - 1.64	0.509
Diabetes mellitus	0.4	0.05 - 2.81	0.348
Hypertension	1.5	0.48 - 4.52	0.502

Categorical variables are presented as numbers (%). Continuous values are expressed as mean ± SD. The baseline category for each variable is the presence of the characteristic, unless indicated otherwise. BMI, body mass index. OR, odds ratio. \*Logistic regression, adjustment for all variables in the model. *P*-values are presented without Bonferroni correction. \*\**P*-values that are significant after Bonferroni correction.

transsphincteric fistulas and 2.4 for high transsphincteric fistulas. The internal fistula opening of low and high transsphincteric fistulas was located anteriorly in 76.0% and 17.5% respectively ( $P < 0.001$ ). An associated abscess was observed in 4% and 54% respectively ( $P < 0.001$ ). The results of univariate analysis are presented in Table 1. After adjustment for all variables in the logistic regression model, the differences between high and low transsphincteric fistulas regarding location of their internal opening and the presence of associated abscesses remained significant ( $P < 0.001$ ). Both variables remained significant after application of the Bonferroni correction. The results of multivariate analysis are presented in Table 2. In patients with a high transsphincteric fistula, mean age at surgery was higher in men than in women ( $49.3 \pm 9.6$  vs.  $42.6 \pm 10.4$  years). In patients with a low transsphincteric fistula, a similar difference in mean age at surgery was observed between men and women ( $44.3 \pm 11.3$  vs.  $39.8 \pm 12.1$  years).

## DISCUSSION

The most common classification of anal fistulas is based on the course of the fistula tract in relation to the anal sphincters.<sup>1</sup> Although Steltzner was the first to make a distinction between different types of fistulas,<sup>2</sup> it was the classification according to Parks et al., which gained widely acceptance.<sup>1</sup> Of the four main types of fistulas described by Parks et al., the transsphincteric fistula is the second most common type.<sup>1</sup> Usually, a distinction is made between high and low transsphincteric fistulas. High transsphincteric fistulas pass through the upper or middle third of the external anal sphincter, whereas low transsphincteric fistulas traverse the lower third of the external anal sphincter. For many surgeons this classification is useful, because they consider patients with a low transsphincteric fistula eligible for fistulotomy. This procedure is not appropriate for patients with a high transsphincteric fistula. For these patients sphincter preserving techniques, such as transanal advancement flap repair and ligation of the intersphincteric fistula tract are preferable.<sup>3-6</sup> Although the distinction between high and low transsphincteric fistulas is commonly practiced, it is unknown whether these fistulas have similar characteristics or not. To the authors knowledge, no reports are available regarding this aspect.

The present study demonstrated that high transsphincteric fistulas have a male predominance. This is in line with reports in the literature ranging from 2:1 to 5:1.<sup>7-10</sup> Low transsphincteric fistulas were found to occur more frequently in females, resulting in a male-to-female ratio of 1:1. Most anal fistulas occur between the third and fifth decades of life.<sup>7,8</sup> The mean age at surgery in high and low transsphincteric fistulas was 47 and 42 years, indicating that the latter occur more often at a younger age.

Although the differences regarding gender and age were found to be significant in univariate analysis, both variables were no longer significantly different in multivariate analysis. This is probably due to the younger age of our female patients in both groups. In patients with a high transsphincteric fistula, the mean age at surgery was higher in men than in women (49 vs. 43 years). In patients with a low transsphincteric fistula, a similar difference in mean age at surgery was observed between men and women (44 vs. 40 years). Transsphincteric fistulas are often associated with one or more abscesses. Marks and Ritchie reported associated abscesses in 28% of all transsphincteric fistulas.<sup>8</sup> In a previous study, examining the complexity of high transsphincteric fistulas, we observed associated abscesses in 36% of the patients. Abscesses occurred more frequently in patients with an internal opening located posteriorly than anteriorly (47% vs. 5%).<sup>11</sup> In the present study, the incidence of associated abscesses was 54% in patients with a high transsphincteric fistula and 4% in those with a low transsphincteric fistula. Since our institution is a tertiary referral centre, we tend to see complex fistulas, which may partially explain the high incidence of associated abscesses in our patients with a high transsphincteric fistula. The different incidence of associated abscesses between high and low transsphincteric fistulas remained significant after adjustment for all variables in the logistic regression model. The internal opening of low and high transsphincteric fistulas was found to be located anteriorly in 76% and 18%. This difference remained statistically significant in multivariate analysis. Our findings suggest a correlation between the location of the internal opening and the presence of concomitant abscesses. Low transsphincteric fistulas have a predilection for the anterior side of the anal canal and are rarely associated with abscesses. High transsphincteric fistulas are almost exclusively located posteriorly and are accompanied by one or more abscesses in more than half of the patients.

The observation that low transsphincteric fistulas occur more frequently in females is difficult to explain. Such fistulas are predominantly located anteriorly. A possible explanation might be that females have more anal glands at the anterior side of the anal canal than men, but in a landmark study by Ian McColl no gender difference was observed in the distribution of anal glands.<sup>12</sup> Based on current data, it seems unlikely that gender-specific distribution of anal glands can explain our finding that low transsphincteric fistulas occur more often in women.

The results of our observational study may have implications for clinical practice. In patients with a low transsphincteric fistula, fistulotomy is still advocated as the treatment of choice because it is considered a simple, effective and safe procedure with a minimal risk of incontinence. The data suggest, however, that fecal continence is at risk following division of the lower third of the external anal sphincter, especially in females with an anterior fistula.<sup>13,14</sup> Female patients are probably at risk because they have a shorter external anal sphincter, which is prone to damage during childbirth.<sup>15,16</sup>

In the present study almost half the patients with a low transsphincteric fistula were female. In these patients sphincter preserving techniques such as ligation of the intersphincteric fistula tract may be preferable to conventional fistulotomy.

There are two limitations of this study. First this study is retrospective and second there is a potential selection bias, because our institution is a tertiary referral center for transsphincteric fistulas. The strengths of the study include the large number of patients, the large number of variables studied and the homogeneity of both patient groups.

In summary the study shows that high and low transsphincteric fistulas have different characteristics. Although not significant in multivariate analysis, low transsphincteric fistulas occurred more frequently at a younger age and more often in females. These fistulas were predominantly anterior and were rarely associated with an abscess.

## REFERENCES

1. Parks AG, Gordon PH, Hardcastle JD. A classification of fistula-in-ano. *Br J Surg*. 1976;63:1-12.
2. Steltzner F. *Die anorectalen Fisteln*. Berlin: Springer-Verlag 1959.
3. Schouten WR, Zimmerman DDE, Briel JW. Transanal advancement flap repair of transsphincteric fistulas. *Dis Colon Rectum*. 1999;42:1419-1422.
4. Rojanasakul A. LIFT procedure: a simplified technique for fistula-in-ano. *Tech Coloproctol*. 2009;13:237-240.
5. Van Onkelen RS, Gosselink MP, Schouten WR. Is it possible to improve the outcome of transanal advancement flap repair for high transsphincteric fistulas by additional ligation of the intersphincteric fistula tract? *Dis Colon Rectum*. 2012;55:163-166.
6. Van Onkelen RS, Gosselink MP, Schouten WR. Ligation of the intersphincteric fistula tract in low transsphincteric fistula: a new technique to avoid fistulotomy. *Colorectal Dis*. 2013;15:587-591.
7. Sainio P. Fistula-in-ano in a defined population. Incidence and epidemiological aspects. *Ann Chir Gynaecol*. 1984;73:219-224.
8. Marks CG, Ritchie JK. Anal fistulas at St Mark's Hospital. *Br J Surg*. 1977;64:84-91.
9. Shouler PJ, Grimley RP, Keighley MR, et al. Fistula-in-ano is usually simple to manage surgically. *Int J Colorect Dis*. 1986;1:113-115.
10. Vasilevsky CA, Gordon PH. Results of treatment of fistula-in-ano. *Dis Colon Rectum*. 1985;28:225-231.
11. Mitalas LE, Dwarkasing RS, Verhaaren R et al. Is the outcome of transanal advancement flap repair affected by the complexity of high transsphincteric fistulas? *Dis Colon Rectum*. 2011;54:857-862.
12. McColl I. The comparative anatomy and pathology of anal glands. *Ann R Coll Surg Engl*. 1967;40:36-67.
13. Van Tets WF, Kuijpers HC. Continence disorders after anal fistulotomy. *Dis Colon Rectum*. 1994;37:1194-1197.
14. Garcia-Aguilar J, Belmonte C, Wong WD, et al. Anal fistula surgery. Factors associated with recurrence and incontinence. *Dis Colon Rectum*. 1996;39:723-729.
15. Sultan AH, Michael CB, Kamm A, et al. Anal-sphincter disruption during vaginal delivery. *New Engl J Med*. 1993;329:1905-1911.
16. Fitzpatrick M, Fynes M, Cassidy M, et al. Prospective study of the influence of parity and operative technique on the outcome of primary anal sphincter repair following obstetrical injury. *Eur J Obstet Gynecol Reprod Biol*. 2000;89:159-163.





## Chapter 3

# **Predictors of outcome after transanal advancement flap repair for high transsphincteric fistulas**

R.S. van Onkelen, M.P. Gosselink, S. Thijsse and W.R. Schouten

*Diseases of the Colon and Rectum 2014;57:1007-1011*

## ABSTRACT

### Background

Transanal advancement flap repair fails in one of every three patients with a high transsphincteric fistula. It has been reported that smoking, obesity and previous attempts at repair adversely affect the outcome of transanal advancement flap repair. Because these findings could not be confirmed by other studies, it is still unclear whether these and other factors have an impact on the outcome. The aim of this study was to identify predictors of outcome in a large cohort of patients who underwent transanal advancement flap repair for a high transsphincteric fistula.

### Method

A consecutive series of 252 patients with a high transsphincteric fistula of cryptoglandular origin were included. Patients with a rectovaginal or Crohn fistula were excluded. All patients underwent transanal advancement flap repair. Preoperatively, patients underwent endoanal magnetic resonance imaging. Seventeen patient and fistula related variables were assessed. The study was performed as a retrospective review.

### Results

Median duration of follow-up was 21 (range, 6-136) months. Failure rate at 3 years was 41% (95% CI 34.0-48.0). None of the studied variables predicted the outcome of flap repair except horseshoe extension. In univariate and multivariate analysis, significantly less failures were observed in patients with horseshoe extension ( $P < 0.05$ ).

### Conclusion

Of all studied variables horseshoe extension was found to be the only positive predictor of outcome after flap repair for high transsphincteric fistulas.

## INTRODUCTION

Fistulotomy is the only fistula treatment that actually works most of the time.<sup>1,2</sup> A major drawback of this procedure is the need for sphincter division with the risk of subsequent fecal continence disturbances.<sup>2-4</sup> Therefore, fistulotomy is inappropriate for patients with a high transsphincteric fistula, passing through the upper or middle third of the external anal sphincter. The main objective in the treatment of high transsphincteric fistulas is healing without impairment of fecal continence. Therefore, sphincter preserving procedures have been developed for the treatment of high transsphincteric fistulas, such as transanal advancement flap repair (TAFR) and ligation of the intersphincteric fistula tract (LIFT).<sup>5-7</sup> Initially, reported healing rates after TAFR varied between 84% and 100%.<sup>8-11</sup> However, it has become clear that TAFR fails in one of every three patients.<sup>12-18</sup> It has been reported that smoking, obesity and previous attempts at repair adversely affect the outcome of TAFR.<sup>13,17,19,20</sup> Because these findings could not be confirmed by other studies, it is still unclear whether these and other factors have an impact on the outcome of TAFR.<sup>17,18,20-22</sup> The aim of this study was to identify predictors of outcome in a large cohort of patients who underwent TAFR.

## METHOD

### Study design

Between 2000 and 2012, a consecutive series of 252 patients with a high transsphincteric fistula of cryptoglandular origin, underwent a TAFR as their first intervention at the Division of Colon and Rectal Surgery, Erasmus MC. In our institution, this was the treatment of choice for all patients with a high transsphincteric fistula. Before the procedure, patients underwent endoanal MRI to depict the course of the fistula tract and to determine the presence and location of associated abscesses. Patients with a rectovaginal fistula or a fistula attributed to Crohn's disease were excluded from this study. Patients who underwent TAFR with additional procedures were excluded. All patients provided informed consent meeting the standards set by the hospital's Institutional Review Board. All operations were performed by one surgeon (W.R.S.) and several colorectal surgery fellows.

### Operative technique

Patients underwent complete mechanical bowel preparation (polyethylene glycol: Klean-prep® Helsinn Birex Pharmaceuticals, Dublin, Ireland). After induction of general endotracheal anaesthesia, metronidazole (500 mg) together with cefuroxime

(1500 mg) was administered intravenously. The patient was placed in prone jack-knife position with the buttocks taped apart. Initially a Parks' retractor (Park's Anal Retractor, Slidell, LA) was used to expose the internal opening of the fistula. Since 2003, Lone Star Retractor was used for this purpose (Lone Star Retractor System, Lone Star Medical Products®, Inc. Houston, TX). The internal opening was enlarged and the remaining crypt-bearing tissue was excised. A small rim of the anodermis, below the internal opening, was excised to create a neodentate line. The defect in the internal anal sphincter was closed with absorbable sutures (2-0 Vicryl, Ethicon, Inc., Somerville, NJ). A flap consisting of mucosa, submucosa and some of the most superficial fibers of the internal anal sphincter, was raised from the level of the dentate line and mobilized over a distance of 4 to 6 centimeters proximally. The flap was advanced and sutured to the neodentate line with absorbable sutures (2-0 Monocryl, Ethicon, Inc., Somerville, NJ).

### **Postoperative care**

All patients were prescribed a stool softener for 2 weeks. There was no diet restriction. Patients were instructed to take a sitz bath 2 to 3 times daily until the wound was healed. After discharge patients were advised to restrict physical activity for 2 weeks.

### **Follow-up**

Patient visits were scheduled 2 weeks, 8 weeks and 6 months after surgery. Healing of the fistula was defined as complete wound healing and closure of all external openings in combination with absence of symptoms. Follow-up information regarding failure was obtained from medical charts or a follow-up telephone call by one author who had not participated in the surgical procedure.

### **Assessment of predictors**

The following 17 patient and fistula related variables were assessed: age, sex, previous attempts at repair, TAFR before referral, presence of associated abscesses, preoperative seton drainage, location of the internal opening, horseshoe extension, postoperative drainage, overweight, obesity, smoking, alcohol consumption, diabetes and hypertension. Age was defined as <45 years or ≥45 years. Previous attempts at repair were defined as one or more surgical attempts at repair prior to referral. Drainage with a seton until the day of TAFR was defined as preoperative seton drainage. Location of the internal opening and horseshoe extension were assessed by EA MRI and careful examination during the procedure. Location of the internal fistula opening was described as anterior or posterior. Body mass index was calculated by dividing the patient's body mass (kilograms) by the square of their height (meters). In accordance to the World Health Organisation overweight was defined as a body

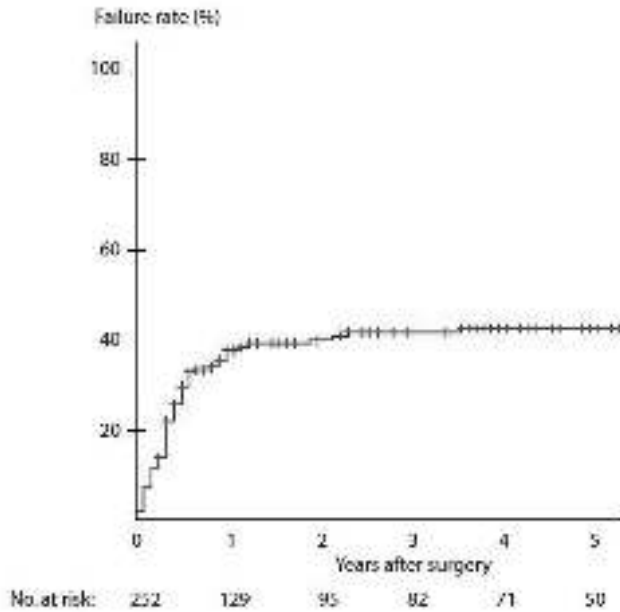
mass index between 25 and 30, and obesity was defined as a body mass index of 30 or more. Smoking was classified as excessive if the patient smoked 10 or more cigarettes a day. Diabetes mellitus and hypertension were included as potential predictive factors if the patient used blood glucose-lowering medication or antihypertensive drugs respectively. These aspects and other details regarding lifestyle such as smoking and alcohol consumption were obtained from the preoperative checklists. Further information was obtained from medical charts or a follow-up telephone call by one author who had not participated in the surgical procedure.

### Statistical analysis

The risk of failure was calculated according to the Kaplan-Meier method. Comparisons between groups were done using the log-rank test. Data are presented as failure rates at 3 years after surgery. Multivariate analysis was performed by Cox regression of the significant variables. Variables used, were those with a  $P$ -value  $\leq 0.05$  according to univariate analysis, as well as age and sex. The  $P$ -value threshold used for significance was 0.05 and all tests were two-sided. Data were analyzed with SPSS IBM software version 20.0 for Windows (SPSS Inc, Chicago, IL).

## RESULTS

The median duration of follow-up was 21 (range, 6-136) months. Failure rate at 3 years after TAFR was 41% (95% CI 34.0-48.0) (Figure 1). Failure was not influenced by age and sex, nor by smoking and obesity. None of these or other patient related factors (presented in Table 1) was found to be an independent and significant predictor of failure after TAFR. Fistula related factors, such as previous attempts at repair, TAFR before referral, preoperative seton drainage, presence of associated abscesses, location of the internal fistula opening, and postoperative drainage, did not affect the outcome of TAFR (Table 2). In contrast to our expectations, the failure rate in patients with horseshoe extension was significantly lower than in patients with a more simple fistula with a direct course (32% (95% CI 23.0-41.0) vs. 51% (95% CI 40.6-61.4);  $P=0.005$ ). After adjustment for age and sex, this finding remained statistical significant ( $P=0.008$ ; Table 3).



**Figure 1.** Kaplan-Meier curve of failure rate after transanal advancement flap repair

**Table 1.** Patient related factors and failure rate of transanal advancement flap repair (n = 252)

	n	Failure rate at 3 years	95% Confidence interval	P-value
<b>Age</b>				
< 45 years	103 (41)	47	35.6 - 58.4	0.164
≥ 45 years	149 (59)	36	27.4 - 44.6	
<b>Sex</b>				
Male	180 (71)	37	29.0 - 45.0	0.116
Female	72 (29)	50	36.9 - 63.1	
<b>Overweight, BMI 25-30</b>				
Yes	108 (57)	40	31.4 - 48.6	0.777
No	82 (43)	39	27.1 - 50.9	
<b>Obesity, BMI ≥ 30</b>				
Yes	57 (23)	35	21.3 - 48.7	0.943
No	190 (77)	40	32.0 - 48.0	
<b>Smoking</b>				
Yes	102 (42)	39	28.4 - 49.6	0.599
No	142 (58)	39	29.7 - 48.2	
<b>Excessive smoking</b>				
Yes	84 (35)	36	24.4 - 47.6	0.188
No	159 (65)	41	32.2 - 49.8	

**Table 1.** (continued)

	n	Failure rate at 3 years	95% Confidence interval	P-value
Alcohol consumption				
Yes	147 (61)	35	26.2 - 43.8	0.083
No	96 (39)	46	34.6 - 57.4	
Diabetes mellitus				
Yes	9 (4)	37	3.5 - 70.5	0.690
No	223 (96)	41	33.6 - 48.4	
Hypertension				
Yes	26 (11)	39	18.8 - 59.2	0.733
No	206 (89)	42	34.2 - 49.8	

Univariate analysis. Variables are presented as numbers (%). Failure rates are presented in percentages. BMI = body mass index.

**Table 2.** Fistula related factors and failure rate of transanal advancement flap repair (n = 252)

	n	Failure rate at 3 years	95% Confidence interval	P-value
Previous attempts at repair				
0	104 (41)	39	27.8 - 50.2	0.400
≥ 1	148 (59)	42	33.2 - 50.8	
Two or more previous attempts at repair				
≤ 1	184 (73)	39	30.8 - 47.2	0.445
≥ 2	68 (27)	44	31.1 - 56.9	
TAFR prior to referral				
Yes	35 (14)	52	33.6 - 70.4	0.091
No	217 (86)	39	31.6 - 46.4	
Preoperative seton drainage				
Yes	38 (15)	27	11.1 - 42.9	0.104
No	214 (85)	43	35.4 - 50.6	
Associated abscesses				
Yes	116 (46)	42	32.0 - 52.0	0.342
No	136 (54)	39	29.4 - 48.6	
Location of the internal opening				
Anterior	50 (20)	36	21.1 - 50.9	0.549
Posterior	202 (80)	42	34.1 - 49.9	
Horseshoe extension				
Yes	117 (46)	32	23.0 - 41.0	0.005
No	135 (54)	51	40.6 - 61.4	
Postoperative drainage				
Yes	116 (46)	42	32.0 - 52.0	0.342
No	136 (54)	39	29.4 - 48.6	

Univariate analysis. Variables are presented as numbers (%). Failure rates are presented in percentages. TAFR = transanal advancement flap repair.

**Table 3.** Cox regression of horse shoe extension adjusted for age and sex (n = 252)

	n	HR	95% HR Confidence interval	P-value
Horseshoe extension				
Yes	117 (46.4)	1	-	0.008
No	135 (53.6)	1.8	1.2 - 2.7	
Age				
< 45 years	103 (40.9)	1.2	0.8 - 1.9	0.433
≥ 45 years	149 (59.1)	1	-	
Sex				
Male	180 (71.4)	1	-	0.220
Female	72 (28.6)	1.3	0.8 - 2.1	

Multivariate analysis. Variables are presented as numbers (%). HR = hazard ratio.

## DISCUSSION

In a consecutive series of 252 patients with a high transsphincteric fistula of cryptoglandular origin who underwent a TAFR at our institution, 17 potential predictors of outcome were assessed. Our study showed that TAFR is an attractive sphincter preserving treatment for high transsphincteric fistulas and that the outcome of TAFR was significantly better in patients with horseshoe extension.

Limitations of this study are the retrospective nature, a single surgeon series and a potential selection bias caused by the tertiary referral center status of our institution. Strengths of the study are the large number of patients, the large number of variables studied, the homogeneity of the patient group, and the long median duration of follow-up.

According to Garcia-Aguilar et al. various factors are associated with recurrence after fistula surgery, including complex type of fistula, horseshoe extension, lack of identification or lateral location of the internal fistulous opening, previous fistula surgery and the surgeon performing the procedure.<sup>4</sup> These factors were analyzed in more than 600 patients who underwent fistula surgery. However, in only 3 out of 108 patients with a transsphincteric fistula was a flap repair performed. Data obtained from this study did not elucidate the value of these factors as a predictor of outcome of flap repair.

Complex type of fistula and lack of identification of the internal fistulous opening has also been identified as predictors of outcome by Jordan et al..<sup>23</sup> These authors examined a heterogeneous group of 279 patients who underwent a great variety of procedures. However, the small number of patients that underwent a flap repair (26 out of 53 patients with a high transsphincteric fistula) was one of the limitations of



this study. A previous study, conducted at our institution, revealed that the complexity of high transsphincteric fistulas, characterized by horseshoe extensions and the presence of associated abscesses, does not affect the outcome of flap repair. In contrast to our expectations, the healing rate of fistulas with a direct course was significantly lower than the healing rate of fistulas with horseshoe extension.<sup>24</sup> This is consistent with the findings of the present study.

Special attention has also been given to the history of previous attempts at repair as potential predictor of outcome. It has been suggested that flap repair is less feasible in an area of scar tissue with reduced blood supply. Ellis and Clark performed a flap repair in 68 patients. They observed a significant higher recurrence rate in the patients with a history of previous attempts at repair. Their patient group, however, was not homogeneous and consisted of 39 women with a rectovaginal fistula and 29 patients with a transsphincteric fistula.<sup>19</sup> The question is whether their conclusion is justified in view of the small number of patients with a transsphincteric fistula. An earlier study, conducted at our own institution, involved 44 patients and revealed that the outcome after flap repair was less favorable in patients who had undergone two or more previous attempts at repair.<sup>13</sup> This earlier finding could not be confirmed by the present study, which was composed of a large, homogeneous group of 252 patients. It seems likely that our earlier conclusion was premature because of the small number of patients. Three other studies also revealed that previous attempts at repair do not adversely affect the outcome after TAFR.<sup>18,21,22</sup> Therefore, it seems unlikely that a history of previous attempts at repair is an independent predictor of outcome after TAFR. This proposition is supported by our observation that even previous flap repairs, performed before referral, did not affect the healing rate. This is in accordance with the finding that repeat flap repairs are worthwhile and successful in two of every three patients.<sup>25</sup>

Smoking is another aspect that received attention. A previous study, conducted at our institution revealed that excessive smoking (more than 10 cigarettes a day) adversely affects the outcome of TAFR.<sup>17</sup> It was suggested that smoking may have a detrimental effect on rectal mucosal blood flow, thereby contributing to disruption of the flap. In an additional study, we observed that rectal mucosal blood flow before and shortly after TAFR was not significantly lower in patients who smoke than in those who do not. Furthermore, it was shown that rectal mucosal blood flow did not affect the outcome of TAFR.<sup>26</sup> Therefore, there was still doubt as to the adverse effect of smoking on fistula healing after flap repair. Ellis and Clark are the only ones, who also observed a lower healing rate after flap repair among smokers.<sup>19</sup> This adverse effect, however, could not be demonstrated by others.<sup>20,21</sup> The present study shows that even excessive smoking is not an independent predictor of outcome for flap repair.

Recently, Schwandner reported that obesity, defined as a body mass index (BMI) higher than 30, is a negative predictive factor for the outcome after flap repair.<sup>20</sup> This finding is not in accordance with the data obtained from the present study, demonstrating that healing is not affected by overweight (BMI 25-30) or obesity (BMI  $\geq$  30). Similar findings were reported by Zimmerman et al.<sup>17</sup>

This study shows that the outcome after TAFR for high transsphincteric fistulas is significantly better in patients with horseshoe extension. An explanation for this unexpected finding might be the possibility that the course of the fistula depends on the severity of the fistulous disease. The more fulminant the fistulous disease, the more perpendicular the fistula might traverse through the anal sphincters, resulting in a direct course to the external fistula opening. Further research is warranted to investigate this aspect.

## REFERENCES

1. Whiteford MH, Kilkenny J, 3rd, Hyman N, et al. Practice parameters for the treatment of perianal abscess and fistula-in-ano (revised). *Dis Colon Rectum*. 2005;48:1337-1342.
2. Westerterp M, Volkers NA, Poolman RW, et al. Anal fistulotomy between Skylla and Charybdis. *Colorectal Dis*. 2003;5:549-551.
3. Van Tets WF, Kuijpers HC. Continence disorders after anal fistulotomy. *Dis Colon Rectum*. 1994;37:1194-1197.
4. Garcia-Aguilar J, Belmonte C, Wong WD, et al. Anal fistula surgery. Factors associated with recurrence and incontinence. *Dis Colon Rectum*. 1996;39:723-729.
5. Rojanasakul A, Pattanaarun J, Sahakitrungruang C, et al. Total anal sphincter saving technique for fistula-in-ano; the ligation of intersphincteric fistula tract. *J Med Assoc Thai*. 2007;90:581-586.
6. Van Onkelen RS, Gosselink MP, Schouten WR. Is it possible to improve the outcome of transanal advancement flap repair for high transsphincteric fistulas by additional ligation of the intersphincteric fistula tract? *Dis Colon Rectum*. 2012;55:163-166.
7. Van Onkelen RS, Gosselink MP, Schouten WR. Ligation of the intersphincteric fistula tract in low transsphincteric fistulae: a new technique to avoid fistulotomy. *Colorectal Dis*. 2012;15:587-591.
8. Wedell J, Meier zu Eissen P, Banzhaf G, et al. Sliding flap advancement for the treatment of high level fistulae. *Br J Surg*. 1987;74:390-391.
9. Oh C. Management of high recurrent anal fistula. *Surgery*. 1983;93:330-332.
10. Kodner IJ, Mazor A, Shemesh EI, et al. Endorectal advancement flap repair of rectovaginal and other complicated anorectal fistulas. *Surgery*. 1993;114:682-689.
11. Aguilar PS, Plasencia G, Hardy TG Jr, et al. Mucosal advancement in the treatment of anal fistula. *Dis Colon Rectum*. 1985;28:496-498.
12. Miller GV, Finan PJ. Flap advancement and core fistulectomy for complex rectal fistula. *Br J Surg*. 1998;85:108-110.
13. Schouten WR, Zimmerman DDE, Briel JW. Transanal advancement flap repair of transsphincteric fistulas. *Dis Colon Rectum*. 1999;42:1419-1422.
14. Sonoda T, Hull T, Piedmonte MR, et al. Outcomes of primary repair of anorectal and rectovaginal fistulas using the endorectal advancement flap. *Dis Colon Rectum*. 2002;45:1622-1628.
15. Van der Hagen SJ, Baeten CG, Soeters PB, et al. Long-term outcome following mucosal advancement flap for high perianal fistulas and fistulotomy for low perianal fistulas: recurrent perianal fistulas: failure of treatment or recurrent patient disease? *Int J Colorectal Dis*. 2006;21:784-790.
16. Van der Hagen SJ, Baeten CG, Soeters PB, et al. Staged mucosal advancement flap for the treatment of complex anal fistulas: pretreatment with noncutting setons and in case of recurrent multiple abscesses a diverting stoma. *Colorectal Dis*. 2005;7:513-518.
17. Zimmerman DDE, Delemarre JBVM, Gosselink MP, et al. Smoking affects the outcome of transanal mucosal advancement flap repair of transsphincteric fistulas. *Br J Surg*. 2003;90:351-354.
18. Mizrahi N, Wexner SD, Zmora O, et al. Endorectal advancement flap: are there predictors of failure? *Dis Colon Rectum*. 2002;45:1616-1621.
19. Ellis CN, Clark S. Effect of tobacco smoking on advancement flap repair of complex anal fistulas. *Dis Colon Rectum*. 2007;50:459-463.

20. Schwandner O. Obesity is a negative predictor of success after surgery for complex anal fistula. *BMC Gastroenterology*. 2011;11:61.
21. Van Koperen PJ, Wind J, Bemelman WA, et al. Long-term functional outcome and risk factors for recurrence after surgical treatment for low and high perianal fistulas of cryptoglandular origin. *Dis Colon Rectum*. 2008;51:1475-1481.
22. Uribe N, Millán M, Minguez M, et al. Clinical and manometric results of endorectal advancement flaps for complex anal fistula. *Int J Colorectal Dis*. 2007;22:259-264.
23. Jordán J, Roig JV, Garcia-Armengol J, et al. Risk factors for recurrence and incontinence after anal fistula surgery. *Colorectal Dis*. 2010;12:254-260.
24. Mitalas LE, Dwarkasing RS, Verhaaren R, et al. Is the outcome of transanal advancement flap repair affected by the complexity of high transsphincteric fistulas? *Dis Colon Rectum*. 2011;54:857-862.
25. Mitalas LE, Gosselink MP, Zimmerman DDE, et al. Repeat transanal advancement flap repair: impact on the overall healing rate of high transsphincteric fistulas and on fecal continence. *Dis Colon Rectum*. 2007;50:1508-1511.
26. Mitalas LE, Schouten SB, Gosselink MP, et al. Does rectal mucosal blood flow affect the outcome of transanal advancement flap repair? *Dis Colon Rectum*. 2009;52:1395-1399.





## Chapter 4

# **Is it possible to improve the outcome of transanal advancement flap repair for high transsphincteric fistulas by additional ligation of the intersphincteric fistula tract?**

R.S. van Onkelen, M.P. Gosselink and W.R. Schouten

*Diseases of the Colon and Rectum 2012;55:163-166*

## ABSTRACT

### Background

Transanal advancement flap repair is successful in two of every three patients with a cryptoglandular fistula passing through the middle or upper third of the external anal sphincter. It has been suggested that ongoing disease in the remaining fistula tract contributes to failure. Ligation of the intersphincteric fistula tract might be a useful tool to eradicate this ongoing disease. The aim of the present study was to evaluate the effect of an additional ligation of the fistula tract on the outcome of transanal advancement flap repair.

### Method

A consecutive series of 41 patients with a high transsphincteric fistula of cryptoglandular origin were included. Ligation of the intersphincteric fistula tract was performed in addition to flap repair. Early and late complications were recorded. Continence scores were determined with the use of the Fecal Incontinence Severity Index.

### Results

Median duration of follow-up was 15 months. Primary healing was observed in 21 patients (51%). Of the 20 patients with a failure, the original transsphincteric fistula persisted in 12 patients. In 8 patients, the transsphincteric fistula was converted into an intersphincteric fistula. These patients underwent subsequent fistulectomy, which was successful in all of them. The overall healing rate was 71%.

### Conclusion

Ligation of the intersphincteric fistula tract procedure is prone to infection and does not enhance the outcome of flap repair.



## INTRODUCTION

Fistulotomy is the only fistula treatment that actually works most of the time.<sup>1,2</sup> A major drawback of this procedure is the need for sphincter division with subsequent continence disturbances.<sup>3,4</sup> Therefore, fistulotomy is not appropriate for patients with a transsphincteric fistula, passing through the upper or middle third of the external anal sphincter. The principal goal in the treatment of high transsphincteric fistulas is healing without impaired continence. In contrast to fistulotomy, transanal advancement flap repair (TAFR) provides a more useful tool to minimize sphincter damage.<sup>5-11</sup> However, it has become clear that this procedure fails in 1 of every 3 patients.<sup>3,5,8-10</sup> Until now, no predictive factors for failure have been identified. In a previous study performed at our institution, the outcome of repeat flap repair was examined in 26 patients, who encountered a failure after the initial procedure.<sup>12</sup> In all of these patients complete healing of the advancement flap was noticed, except at the site of the original internal opening. This remarkable clinical finding and the lack of predictive factors for failure have made the question of whether ongoing disease in the remaining tract contributes to persistence of the fistula after flap repair. Most of the remaining tract is located in the intersphincteric plane near the origin of the fistula. Recently, ligation of the intersphincteric fistula tract (LIFT) has been introduced as an attractive sphincter-preserving alternative.<sup>13-18</sup> Based on the promising results of this new technique, it was questioned whether this procedure would be a useful candidate for the eradication of the ongoing disease in the remaining fistula tract, thereby improving the outcome of TAFR. The present study was conducted to assess the effect of an additional LIFT procedure on the outcome of TAFR and to evaluate the impact of both combined procedures on fecal continence.

## METHOD

Between June 2009 and December 2010, a consecutive series of 41 patients with a high transsphincteric fistula of cryptoglandular origin underwent a LIFT procedure in addition to their flap repair. Patients with a rectovaginal fistula or a fistula due to Crohn's disease were excluded from this study. The present series comprised 32 men and 9 women. Median age at the time of treatment was 42 (range, 20-69) years. Twenty-one patients had undergone one or more previous attempts at repair before referral. All patients provided written informed consent meeting the standards set by the hospital's institutional review board. All operations were performed by one surgeon (W.R.S.).

## Operative technique

All patients received complete mechanical bowel preparation (polyethylene glycol: Klean-prep Helsinn Birex Pharmaceuticals, Dublin, Ireland). After induction of general endotracheal anesthesia, metronidazole (500 mg) together with cefuroxime (1500 mg) was administered intravenously. The patient was placed in a prone jackknife position with the buttocks taped apart. The internal opening of the fistula was exposed by the use of a Lone Star retractor (Lone Star Retractor System, Lone Star Medical Products, Inc. Houston, TX). Then, a probe was introduced into the fistula tract. A curvilinear incision was made, just outside the intersphincteric groove. Dissection was continued in the intersphincteric plane until the fistula tract was encountered. After isolation of the fistula tract, the probe was removed and the tract was ligated with synthetic absorbable polyglactin sutures (3/0 Vicryl, Ethicon, Inc., Somerville, NJ) close to the internal and external anal sphincter. The tract was then transected between the 2 ligation points. Finally, the wound was loosely closed with interrupted, synthetic non-absorbable nylon sutures (3/0 Ethilon, Ethicon, Norderstedt, Germany). Subsequently, the external opening was enlarged and the fistula tract was excised as far as possible until the outer border of the external anal sphincter. The crypt-bearing tissue around the internal opening as well as the overlying anodermis was then excised. The defect in the internal anal sphincter was closed with absorbable sutures. A flap consisting of mucosa, submucosa, and some of the most superficial fibers of the internal anal sphincter was raised from the level of the dentate line and mobilized over a distance of 4 to 6 cm proximally. The flap was advanced and sutured to the neodentate line with absorbable sutures.

## Postoperative care

All patients were immobilized for 5 days. During these days, they received a clear liquid diet. During this period, metronidazole and cefuroxime were administered intravenously 3 times daily.

## Follow-up

Patient visits were scheduled 2 weeks, 3 months, and 6 months after surgery. Healing of the fistula was defined as complete wound healing and closure of all external openings in combination with absence of symptoms. Additional follow-up information was obtained from both a questionnaire and telephone communication by one author who had not participated in the surgical procedure.

## Assessment of fecal continence

Fecal continence was evaluated by use of the Rockwood Fecal Incontinence Severity Index (RFISI). This index was assessed before and 6 months after the procedure.

## Statistical analysis

For statistical analysis the Fisher exact probability test was used. The limit of statistical significance was set at  $P=0.05$ .

## RESULTS

The median duration of follow-up was 15 (range, 7-21) months. Primary fistula healing was observed in 21 patients (51%). Four of these patients (19%) encountered purulent discharge at the intersphincteric wound. This problem resolved spontaneously and did not adversely affect the final outcome. In all failures, we noticed complete healing of the flap, except at the site of the original internal opening. Of the 20 patients with a failure, 12 had persistent discharge both at the original external opening and at the intersphincteric wound. In 8 patients, the external component was gone, and discharge occurred only at the intersphincteric wound. This conversion to a low intersphincteric fistula enabled simplified subsequent fistulectomy. This second procedure was successful in all 8 patients, eventually resulting in an overall healing rate of 71%. Of the 12 patients whose surgery failed without an intersphincteric pattern, 4 patients were successfully treated with a repeat TAFR. The other 8 patients were treated with long-term indwelling seton drainage. The median time to failure was within 3 months in all patients. The healing rate was not affected by age, sex of the patients, number of prior attempts, preoperative use of seton drainage for at least 2 months, or fistula characteristics (Table 1). Before the combined procedures, the median RFISI was 10 (range, 0-37). Six months after surgery, the median RFISI score was not changed significantly (RFISI = 7; range, 0-29). The RFISI was found to be improved in 6 patients and worsened in 1 patient. In 34 patients, RFISI did not change after the procedure.

**Table 1.** Comparison of baseline patient and fistula characteristics

Variable	Success	Failure	P-value
Age, median (range)	43 (31-69)	37 (20-67)	0.10
Sex, % male	71	65	0.68
Prior attempts at repair ( $\geq 1$ ), %	42	60	0.35
Preoperative seton drainage, %	38	50	0.45
Fistula duration, months	16	18	0.62
Internal opening, %			
Posterior	76	75	
Anterior	23	20	
Lateral	1	5	0.64
Horseshoe extension, %	29	50	0.14

## DISCUSSION

The main objective in the treatment of transsphincteric fistulas is healing of the fistula without impairment of fecal continence. In patients with a low transsphincteric fistula, passing through the lower third of the external anal sphincter, this goal can be achieved by simple "lay open" fistulotomy.<sup>1,2</sup> This procedure is not appropriate for patients with a high transsphincteric fistula, passing through the middle or upper third of the external anal sphincter. During the past decades, a sphincter-saving procedure such as flap repair, the use of glue and plugs, and recently the LIFT procedure have been introduced as alternative options for the treatment of high transsphincteric fistulas. Although TAFR provides a useful tool to obtain fistula healing without serious impairment of fecal continence, this procedure fails in 1 of every 3 patients.<sup>5</sup> Until now, no predictive factors for failure have been identified. In a previous study, conducted at our institution, the outcome of repeat flap repair was examined in 26 patients, who encountered a failure after the initial procedure.<sup>12</sup> In all of these patients, complete healing of the advancement flap was noticed, except at the site of the original internal opening. This remarkable clinical finding and the lack of predictive factors for failure have raised the question of whether ongoing disease in the remaining tract contributes to persistence of the fistula after flap repair. Previous attempts, including the additional use of glue and plugs, failed to improve the outcome of TAFR.<sup>19-22</sup> Recently, the LIFT procedure has been introduced as a promising sphincter-preserving procedure. Rojanasakul<sup>14</sup> was the first to describe this new technique. He observed primary healing of the fistula in 94% of his patients. Another report from Malaysia also revealed high healing rates, exceeding those obtained with the current sphincter saving techniques.<sup>17</sup> However, recent reports from the United States showed more modest results, indicating that the LIFT procedure, like the flap repair, fails in 1 of every 3 patients.<sup>13,18</sup> The LIFT procedure is based on an original concept of eradication of the fistulous disease at its origin without sphincter damage. Following adequate flap repair, a short tract remains in the intersphincteric plane near the origin of the fistula. It has been suggested that ongoing inflammation in this remaining tract contributes to failure after flap repair. It was questioned whether the LIFT procedure enables the eradication of this ongoing inflammation, thereby improving the results of TAFR. The outcome of the present study, with a primary healing rate of only 51%, is rather disappointing and clearly demonstrates that LIFT provides no benefits. There was no flap loss. In all failures, we noticed complete healing of the flap, except at the site of the original internal opening. This remarkable finding does suggest that ongoing inflammation in the remaining fistula tract contributes to persistence of the fistula, but we were not able to resolve this with addition of the LIFT procedure. In patients treated with TAFR only, progress of residual sepsis is still possible toward the enlarged

external opening. In patients who are treated with LIFT only, the opposite route toward the anal canal is an escape for the ongoing inflammation. The poor healing rate might be caused by entrapment of residual sepsis between the ligation site and the flap. However, conversion of the transsphincteric fistula to a low intersphincteric fistula was the only positive side effect of the additional LIFT procedure. This conversion was observed in 20% of the patients and enabled a subsequent and simplified fistulectomy. This phenomenon has also been reported after ligation of the intersphincteric fistula tract as a single procedure.<sup>13</sup> Following both combined procedures, no deterioration of continence was observed. In the past it had been reported that TAFR is associated with disturbed continence. In a previous study, we were able to demonstrate that the use of a Parks retractor has a deteriorating effect on fecal continence.<sup>23</sup> This side effect was not observed after flap repair with the use of a Lone Star retractor. In the present study, the same retractor was used to gain access to the anal canal. In our opinion, avoidance of anal stretch is the major contributing factor in the preservation of fecal continence. Our conservative postoperative management of inpatient stay, immobilization, clear liquid diet, and postoperative antibiotics is based on expert opinions. We did not change our policy during this study to be able to compare the results with our historical group. In the future, we will introduce an accelerated-stay program including single dose prophylactic antibiotics, paracetamol for analgesia, free oral fluid and food immediately after the operation supplemented by laxatives, and enforced mobilization. Such a regimen seems especially worthwhile after the LIFT procedure. Although randomized controlled trials comparing TAFR and LIFT are lacking, there is some evidence that the LIFT procedure, like the flap repair, also fails in 1 of every 3 patients. Flap repair is rather demanding, whereas LIFT is simple and easy to perform. Furthermore, patients who are approached with the LIFT procedure can be treated as outpatients. Therefore, it is expected that the LIFT procedure will become the first choice for high transsphincteric fistulas. However, flap repair will remain important in case of a persistent fistula after 1 or 2 LIFT procedures and in patients with a fistula not amenable for LIFT, such as those with intersphincteric horseshoe extension or an associated intersphincteric abscess. Until now, all our attempts to improve the outcome of flap repair have failed. In our experience, it is not possible to increase the fistula closure rate after TAFR, either by additional use of glue or plugs, or by combining the flap repair with an additional LIFT procedure as demonstrated in the present study. Failure in 1 of every 3 patients seems to be inevitable.

## REFERENCES

1. Van der Hagen SJ, Baeten CG, Soeters PB, et al. Long-term outcome following mucosal advancement flap for high perianal fistulas and fistulotomy for low perianal fistulas: recurrent perianal fistulas: failure of treatment or recurrent patient disease? *Int J Colorectal Dis.* 2006;21:784-790.
2. Whiteford MH, Kilkenny J III, Hyman N, et al. Practice parameters for the treatment of perianal abscess and fistula-in-ano (revised). *Dis Colon Rectum.* 2005;48:1337-1342.
3. Lunniss PJ, Kamm MA, Phillips RK. Factors affecting continence after surgery for anal fistula. *Br J Surg.* 1994;81:1382-1385.
4. Van Tets WF, Kuijpers HC. Continence disorders after anal fistulotomy. *Dis Colon Rectum.* 1994;37:1194-1197.
5. Mitalas LE, Gosselink MP, Oom DM, et al. Required length of follow-up after transanal advancement flap repair of high transsphincteric fistulas. *Colorectal Dis.* 2008;11:726-728.
6. Aguilar PS, Plasencia G, Hardy TG Jr, et al. Mucosal advancement in the treatment of anal fistula. *Dis Colon Rectum.* 1985;28:496-498.
7. Kodner IJ, Mazor A, Shemesh EI, et al. Endorectal advancement flap repair of rectovaginal and other complicated anorectal fistulas. *Surgery.* 1993;114:682-689.
8. Zimmerman DD, Delemarre JB, Gosselink MP, et al. Smoking affects the outcome of transanal mucosal advancement flap repair of transsphincteric fistulas. *Br J Surg.* 2003;90:351-354.
9. Mizrahi N, Wexner SD, Zmora O, et al. Endorectal advancement flap: are there predictors of failure? *Dis Colon Rectum.* 2002;45:1616-1621.
10. Schouten WR, Zimmerman DD, Briel JW. Transanal advancement flap repair of transsphincteric fistulas. *Dis Colon Rectum.* 1999;42:1419-1422.
11. Ortiz H, Marzo J. Endorectal flap advancement repair and fistulectomy for high transsphincteric and suprasphincteric fistulas. *Br J Surg.* 2000;87:1680-1683.
12. Mitalas LE, Gosselink MP, Zimmerman DD, et al. Repeat transanal advancement flap repair: impact on the overall healing rate of high transsphincteric fistulas and on fecal continence. *Dis Colon Rectum.* 2007;50:1508-1511.
13. Bleier H, Moloo H, Goldberg S. Ligation of the intersphincteric fistula tract (LIFT): an effective new technique for complex fistulae. *Dis Colon Rectum.* 2010;53:43-46.
14. Rojasasakul A. LIFT procedure: a simplified technique for fistula-in-ano. *Tech Coloproctol.* 2009;13:237-240.
15. Rojasasakul A, Pattanaarun J, Sahakitrungruang C, et al. Total anal sphincter saving technique for fistula-in-ano: the ligation of intersphincteric fistula tract. *J Med Assoc Thai.* 2007;90:581-586.
16. Lunniss PJ. LIFT procedure: a simplified technique for fistula-in-ano. *Tech Coloproctol.* 2009;13:241-242.
17. Shanwani A, Azmi M, Amri N. The ligation of intersphincteric fistula tract (LIFT) for fistula-in-ano: sphincter saving technique. *Dis Colon Rectum.* 2010;53:39-42.
18. Aboulian A, Kaji AH, Kumar RR. Early results of ligation of the intersphincteric fistula tract for fistula-in-ano. *Dis Colon Rectum.* 2011;54:289-292.
19. Ellis CN, Clark S. Fibrin glue as an adjunct to flap repair of anal fistulas: a randomized, controlled study. *Dis Colon Rectum.* 2006;49:1736-1740.
20. Mitalas LE, Van Onkelen RS, Gosselink MP, et al. The anal fistula plug as an adjunct to transanal advancement flap repair. *Dis Colon Rectum.* 2010;53:1713.

21. Van Koperen PJ, Wind J, Bemelman WA, et al. Fibrin glue and transanal rectal advancement flap for high transsphincteric perianal fistulas: is there any advantage? *Int J Colorectal Dis.* 2008;23:697-701.
22. Alexander SM, Mitalas LE, Gosselink MP, et al. Obliteration of the fistulous tract with Bio-Glue adversely affects the outcome of transanal advancement flap repair. *Tech Coloproctol.* 2008;12:225-258.
23. Zimmerman DD, Gosselink MP, Hop WC, et al. Impact of two different types of anal retractor on fecal continence after fistula repair: a prospective, randomized clinical trial. *Dis Colon Rectum.* 2003;46:1674-1679.





## Chapter 5

# **Ligation of the intersphincteric fistula tract in low transsphincteric fistulae: A new technique to avoid fistulotomy**

R.S. van Onkelen, M.P. Gosselink and W.R. Schouten

*Colorectal Disease 2013;15:587-591*

## ABSTRACT

### Background

To date fistulotomy is still the treatment of choice for patients with a transsphincteric fistula passing through the lower third of the external anal sphincter, because it is a simple, effective and safe procedure with a minimal risk of incontinence. However, data suggest that the risk of impaired continence following division of the lower third of the external anal sphincter is not insignificant, especially in female patients with an anterior fistula and patients with diminished anal sphincter function. It has been shown that ligation of the intersphincteric fistula tract (LIFT) is a promising sphincter-preserving technique. Therefore, we questioned whether LIFT could replace fistulotomy in patients with a low transsphincteric fistula.

### Method

A consecutive series of 22 patients with a low transsphincteric fistula of cryptoglandular origin underwent LIFT. Continence scores were determined using the Rockwood Fecal Incontinence Severity Index.

### Results

Median follow-up was 19.5 months. Primary healing was observed in 18 (82%) patients. In the four patients without primary healing, the transsphincteric fistula was converted into an intersphincteric fistula. These patients underwent subsequent fistulotomy with preservation of the external anal sphincter. The overall healing rate was 100%. Six months after surgery, the median incontinence score was not changed significantly.

### Conclusion

Low transsphincteric fistulae can be treated successfully by LIFT, without affecting faecal continence. Division of the lower part of the external anal sphincter is no longer necessary in the treatment of low transsphincteric fistulae, which is essential for patients with compromised anal sphincters.

## INTRODUCTION

Fistulotomy is the only fistula treatment that actually works most of the time.<sup>1,2</sup> A major drawback is the need for sphincter division with the risk of a faecal continence disturbance.<sup>3-5</sup> Therefore, fistulotomy is not appropriate for patients with a high transsphincteric fistula, passing through the upper or middle third of the external anal sphincter. Today, sphincter-preserving procedures are available for the treatment of these high transsphincteric fistulae, such as flap repair, the use of glue and plugs, and ligation of the intersphincteric fistula tract (LIFT). For patients with a low transsphincteric fistula fistulotomy is still advocated as the treatment of choice because it is considered a simple, effective and safe procedure with a minimal risk of faecal incontinence. However, data suggest that the risk of diminished faecal continence following division of the lower third of the external anal sphincter is not insignificant, especially in female patients with an anterior fistula.<sup>3,4</sup> Female patients are probably at risk because they have a shorter external anal sphincter anteriorly, which is prone to damage during childbirth.<sup>6,7</sup> Recent findings indicate that for most patients it is more important to minimize their risk of diminished faecal continence than to have a highly successful treatment for their fistula.<sup>8</sup> LIFT is a new sphincter-preserving technique for the treatment of transsphincteric fistulae. The reported healing rates after this procedure are promising.<sup>9-15</sup> We therefore questioned whether fistulotomy, including division of the lower part of the external anal sphincter, may be replaced by LIFT in patients with a low transsphincteric fistula.

## METHOD

Between June 2009 and March 2012, a consecutive series of 22 patients with a low transsphincteric fistula of cryptoglandular origin underwent LIFT. Prior to the procedure all patients underwent endoanal MRI to visualize the course of the fistula tract. Patients with a rectovaginal fistula or a fistula due to Crohn's disease were excluded. The present series included 13 men and nine women. The median age at the time of treatment was 45 (17-59) years. Ten patients had undergone one or more previous attempts at repair before referral. All patients provided informed consent meeting the standards set by the hospital's Institutional Review Board. All operations were performed by one surgeon (WRS).

### Operative technique

After induction of general endotracheal anaesthesia, metronidazole (500 mg) and cefuroxime (1500 mg) were administered intravenously. With the patient in the prone

jack-knife position the internal opening of the fistula was exposed using a lone-star retractor (Lone Star Retractor System; Lone Star Medical Products Inc., Houston, Texas, USA). A probe was then introduced into the fistula track and a curvilinear incision was made, just outside the intersphincteric groove. Dissection was continued in the intersphincteric plane until the fistula track was encountered. After its isolation the probe was removed and the track was ligated with absorbable sutures (3 / 0 Vicryl; Ethicon Inc., Somerville, New Jersey, USA) close to the internal and external anal sphincters. The track was then transected between the two ligation points. The wound was loosely closed with interrupted, non-absorbable sutures (3 / 0 Ethilon; Ethicon, Norderstedt, Germany). Subsequently, the external opening was enlarged and the fistula track was excised as far as possible until the outer border of the external anal sphincter. Postoperatively all patients were prescribed a stool softener for 2 weeks. There was no diet restriction. Patients were instructed to take a sitz bath two to three times daily until the wound was healed. After discharge patients were advised to restrict physical activity for 2 weeks.

### **Follow-up**

Patient visits were scheduled at 2, 8 and 26 weeks after surgery. Healing of the fistula was defined as complete wound healing and closure of all external openings in combination with the absence of symptoms. Further follow-up information was obtained from both a questionnaire and telephone communication by one author who had not participated in the surgical procedure. Faecal continence was evaluated by using the Rockwood Fecal Incontinence Severity Index (RFISI). This index was assessed before and at 26 weeks after the procedure.

### **Statistical analysis**

Fisher's exact probability test was used. The limit of statistical significance was set at  $P = 0.05$ .

## **RESULTS**

Primary fistula healing was observed in 18 (82%) patients. Four patients presented with persisting discharge at the intersphincteric wound after the external component of their fistula had healed. This conversion to a low intersphincteric fistula enabled simplified subsequent fistulotomy without division of the lower part of the external anal sphincter. This second procedure was successful in all four patients, finally resulting in an overall healing rate of 100%. The median duration of follow-up was 19.5 (3-35) months. The median time period to the second procedure was 5 (5-7) months.

**Table 1.** Primary and secondary healing after ligation of the intersphincteric fistula tract

Patient and fistula characteristics	Primary healing (N=18)	Secondary healing (N=4)
Median age (years)	45.5	43.5
Male:female ratio	9:9	4:0
One or more previous attempts at repair	10	0
Preoperative seton drainage	5	1
Location of the internal opening (%)		
Posterior	11	0
Anterior	89	100

The relatively large proportion (41%) of female patients was striking. This observation suggests that low transsphincteric fistulae occur more frequently in women than high transsphincteric fistulae. In almost all (91%) patients the internal opening was located anteriorly in the midline. This location was found in eight of the nine female patients. All female patients showed primary and complete fistula healing (Table 1). The RFISI was filled in by all patients. Prior to LIFT, the median RFISI was 0 (0-20). Six months after the last procedure, it had not changed significantly, 0 (0-10). The RFISI after LIFT, resulting in primary fistula healing, was found to be improved in two patients and deteriorated in none of the others. In the four patients in whom the transsphincteric fistula was converted into an intersphincteric fistula, the RFISI did not deteriorate after subsequent fistulotomy. In the eight female patients in whom the internal fistula opening was located anteriorly in the midline, the median preoperative RFISI was 0 (0-0) and the median postoperative RFISI was 0 (0-0).

## DISCUSSION

Fistulotomy is the only fistula treatment that actually works most of the time.<sup>1,2</sup> For patients with a high transsphincteric fistula, passing through the upper or middle third of the external anal sphincter, fistulotomy is not appropriate because of the high risk of faecal incontinence.<sup>2-4</sup> Fortunately there are sphincter-preserving alternatives such as flap repair, the use of glue and plugs and LIFT.<sup>16</sup> These sphincter-preserving techniques are not applied in the treatment of low transsphincteric fistulae. For patients with a fistula passing through the lower third of the external anal sphincter, fistulotomy is still advocated as the treatment of choice, because it is considered a simple, effective and safe procedure with a minimal risk of incontinence. However, there are indications that impairment of faecal continence is more common than thought. In a recent study, Bokhari and Lindsey<sup>17</sup> observed major and minor incontinence after fistulotomy for low fistulae in 5% and 11% of their patients. They found even higher percent-

ages in patients presenting with one or more of the following compromising factors: anterior fistula in females, pre-existing incontinence, diminished squeeze pressures, sphincter defects on anal ultrasound, previous anal surgery and at-risk obstetric history. Garcia-Aguilar et al. reported major and minor incontinence after fistulotomy for low transsphincteric fistulae in 44% of their patients. They also found that female gender and an internal opening located in the midline anteriorly were predictive factors of impaired continence after fistulotomy.<sup>4</sup> Female patients are probably at risk because they have a shorter external anal sphincter, which is prone to damage during childbirth.<sup>6,7</sup> The incidence of impaired continence after fistulotomy for low anal fistula has been addressed in mostly retrospective studies.<sup>2,4,17-20</sup> In most of these studies impairment of continence was assessed by simple questionnaires and not with validated faecal incontinence grading scores. Manometric data and imaging details regarding the exact course of the fistula tract are generally lacking and remarkably often no distinction is made between intersphincteric and low transsphincteric fistulae. The question is whether this distinction is important or not. Atkin et al.<sup>20</sup> found no difference in the operation-induced continence disturbances after division of the internal anal sphincter alone during fistulotomy for intersphincteric fistulae compared with division of the lower part of both anal sphincters in patients with a transsphincteric fistula. In contrast to this finding, Garcia-Aguilar et al.<sup>4</sup> observed that the rate of incontinence increased linearly with the estimated amount of external anal sphincter divided during fistulotomy. Cavanaugh et al.<sup>21</sup> demonstrated by linear regression that only the amount of external anal sphincter divided correlated with faecal incontinence severity index scores. Based on these findings it seems likely that division of the internal anal sphincter alone is less detrimental than division of both anal sphincters. Although the exact incidence of impaired continence after fistulotomy for low transsphincteric fistula cannot be assessed, the data obtained from the studies conducted so far suggest that continence disturbances are more common than thought after surgical treatment of low fistulae (Table 2). A recent study conducted by Ellis revealed that anal sphincter preservation is the primary concern of most patients. His findings indicate that, within limits, minimizing the risk of diminished continence is of greater importance for most patients than the success rate of the surgical procedure.<sup>8</sup> Given these findings patients with a low transsphincteric fistula would also be eligible for a sphincter-preserving alternative instead of a conventional fistulotomy. LIFT has been introduced as a promising sphincter-preserving alternative to flap repair for high transsphincteric fistula, passing through the middle or upper third of the external anal sphincter. The LIFT procedure is based on an original concept regarding eradication of the fistulous disease at its origin without sphincter damage. Rojanasakul<sup>25</sup> was the first to describe this new technique. He observed primary fistula healing in 94% of his patients. Other reports from Malaysia and Singapore also revealed high healing

**Table 2.** Impairment of faecal continence after fistulotomy for low anal fistula

Author	Year	N	Postoperative incontinence*		
			Minor (%)	Major (%)	Minor and/or Major (%)
Garcia-Aguilar et al. <sup>4</sup>	1996	177			39
Mylonakis et al. <sup>22</sup>	2001	65	9	0	
Westerterp et al. <sup>2</sup>	2003	18	44	0	
Chang and Lin. <sup>23</sup>	2003	45			38
Van der Hagen et al. <sup>18</sup>	2006	62	5	0	
Toyonaga et al. <sup>24</sup>	2007	148			20
Van Koperen et al. <sup>19</sup>	2008	63	41	5	
Bokhari and Lindsey. <sup>17</sup>	2010	53	11	5	
Atkin et al. <sup>20</sup>	2011	51	23	2	

\*Minor incontinence is incontinence for gas and/or soiling. Major incontinence is incontinence for solid and/or liquid stool.

rates, exceeding those obtained with the current sphincter-saving techniques.<sup>11,15</sup> However, recent reports from the USA and Australia indicated that LIFT fails in one of every three patients.<sup>9,12,13</sup> Based on these promising results we questioned whether LIFT could be a good alternative for conventional fistulotomy in patients with a low transsphincteric fistula. The outcome of the present study, with a primary healing rate of 82%, illustrates that LIFT is indeed a good alternative for fistulotomy. In all these patients both anal sphincters could be preserved. In the four (18%) patients without primary healing, the external component of the fistula healed and persistent discharge occurred only at the intersphincteric wound. Such conversion to an intersphincteric fistula has also been reported by others.<sup>9,12-15</sup> This phenomenon suggests that LIFT is sufficient on the side of the external anal sphincter but not always on the side of the internal anal sphincter, resulting in ongoing inflammation in the intersphincteric plane in approximately one of six patients. A recent study, conducted in our hospital, revealed that the intersphincteric track in most perianal fistulae is lined with granulation tissue. The presence of granulation tissue may be suggestive of an inflammatory process.<sup>26</sup> Conversion to an intersphincteric fistula due to ongoing intersphincteric disease requires a second procedure including division of the lower part of the internal anal sphincter. This could be considered a disadvantage of the LIFT procedure, with a potential risk of continence disturbance. After fistulotomy for intersphincteric fistula continence disturbance has been reported in up to 38% of cases.<sup>23</sup> However, in our four patients who underwent a second procedure with division of the lower part of the internal anal sphincter, the RFISI did not change. Since the second procedure was successful in all our four patients, the overall healing rate was 100%. In both patients with primary healing and patients with secondary healing, the external anal sphincter could be preserved in all cases. This, in our opinion, is the great advantage of the

LIFT procedure for patients with a low transsphincteric fistula. The median RFISI did not deteriorate after LIFT, not even after the second procedure with division of the lower part of the internal anal sphincter. Furthermore, the present study revealed two striking features of low transsphincteric fistulae: first, the relatively large proportion of female patients, suggesting that low transsphincteric fistulae occur more frequently in women than high transsphincteric fistulae; and second, the location of the internal fistula opening with a predilection for the anterior midline. Female patients with an anterior fistula in particular are at risk for impaired continence after fistulotomy.<sup>4,17</sup> None of our female patients encountered deterioration of continence after LIFT. LIFT is an attractive alternative to avoid fistulotomy. It seems likely that division of the lower part of the external anal sphincter is no longer necessary in the treatment of low transsphincteric fistulae.



## REFERENCES

1. Whiteford MH, Kilkenny J 3rd, Hyman N, et al. Practice parameters for the treatment of perianal abscess and fistulain- ano (revised). *Dis Colon Rectum*. 2005;48:1337-1342.
2. Westerterp M, Volkers NA, Poolman RW, et al. Anal fistulotomy between Skylla and Charybdis. *Colorectal Dis*. 2003;5:549-551.
3. Van Tets WF, Kuijpers HC. Continence disorders after anal fistulotomy. *Dis Colon Rectum*. 1994;37:1194-1197.
4. Garcia-Aguilar J, Belmonte C, Wong WD, et al. Anal fistula surgery. Factors associated with recurrence and incontinence. *Dis Colon Rectum*. 1996;39:723-729.
5. Lindsey I, Jones OM, Smilgin-Humphreys MM, et al. Patterns of fecal incontinence after anal surgery. *Dis Colon Rectum*. 2004;47:1643-1649.
6. Sultan AH, Michael CB, Kamm A, et al. Anal-sphincter disruption during vaginal delivery. *N Engl J Med*. 1993;329:1905-1911.
7. Fitzpatrick M, Fynes M, CassidyM, et al. Prospective study of the influence of parity and operative technique on the outcome of primary anal sphincter repair following obstetrical injury. *Eur J Obstet Gynecol Reprod Biol*. 2000;89:159-163.
8. Ellis CN. Sphincter-preserving fistula management: what patients want. *Dis Colon Rectum*. 2010;53:1652-1655.
9. Bleier H, Moloo H, Goldberg S. Ligation of the intersphincteric fistula tract (LIFT): an effective new technique for complex fistulas. *Dis Colon Rectum*. 2010;53:43-46.
10. Rojanasakul A, Pattanaarun J, Sahakitrungruang C, et al. Total anal sphincter saving technique for fistula-in-ano; the ligation of intersphincteric fistula tract. *J Med Assoc Thai*. 2007;90:581-586.
11. Shanwani A, Azmi M, Amri N. The ligation of intersphincteric fistula tract (LIFT) for fistula-in-ano: sphincter saving technique. *Dis Colon Rectum*. 2010;53:39-42.
12. Aboulian A, Kaji AH, Kumar RR. Early results of ligation of the intersphincteric fistula tract for fistula-in-ano. *Dis Colon Rectum*. 2011;54:289-292.
13. Ooi K, Skinner I, Croxford M, et al. Managing fistula-in-ano with ligation of the intersphincteric fistula tract procedure: the Western Hospital experience. *Colorectal Dis*. 2011;14:599-603.
14. Sileri P, Franceschilli L, Angelucci GP, et al. Ligation of the intersphincteric fistula tract (LIFT) to treat anal fistula: early results from a prospective observational study. *Tech Coloproctol*. 2011;15:413-416.
15. Tan K, Tan IJ, Lim FS, et al. The anatomy of failures following the ligation of intersphincteric fistula tract technique for anal fistula: a review of 93 patients over 4 years. *Dis Colon Rectum*. 2011;54:1368-1372.
16. Van Onkelen RS, Gosselink MP, Schouten WR. Is it possible to improve the outcome of transanal advancement flap repair for high transsphincteric fistulas by additional ligation of the intersphincteric fistula tract? *Dis Colon Rectum*. 2012;55:163-166.
17. Bokhari S, Lindsey I. Incontinence following sphincter division for treatment of anal fistula. *Colorectal Dis*. 2009;12:135-139.
18. Van der Hagen SJ, Baeten CG, Soeters PB, et al. Long-term outcome following mucosal advancement flap for high perianal fistulas and fistulotomy for low perianal fistulas: recurrent perianal fistulas: failure of treatment or recurrent patient disease? *Int J Colorectal Dis*. 2006;21:784-790.

19. Van Koperen PJ, Wind J, Bemelman WA, et al. Long-term functional outcome and risk factors for recurrence after surgical treatment for low and high perianal fistulas of cryptoglandular origin. *Dis Colon Rectum*. 2008;51:1475-1481.
20. Atkin GK, Martins J, Tozer P, et al. For many high anal fistulas, lay open is still a good option. *Tech Coloproctol*. 2011;15:143-150.
21. Cavanaugh M, Hyman N, Osler T. Fecal incontinence severity index after fistulotomy: a predictor of quality of life. *Dis Colon Rectum*. 2002;45:349-353.
22. Mylonakis E, Katsios C, Godevenos D, et al. Quality of life of patients after surgical treatment of anal fistula; the role of anal manometry. *Colorectal Dis*. 2001;3:417-421.
23. Chang SC, Lin JK. Change in anal continence after surgery for intersphincteric anal fistula: a functional and manometric study. *Int J Colorectal Dis*. 2003;18:111-115.
24. Toyonaga T, Matsushima M, Kiriu T, et al. Factors affecting continence after fistulotomy for intersphincteric fistula-in-ano. *Int J Colorectal Dis*. 2007;22:1071-1075.
25. Rojanasakul A. LIFT procedure: a simplified technique for fistula-in-ano. *Tech Coloproctol*. 2009;13:237-240.
26. Mitalas LE, van Onkelen RS, Monkhorst K, et al. Identification of epithelialization in high trans-sphincteric fistulas. *Tech Coloproctol*. 2012;16:113-117.





## Chapter 6

# **Treatment of anal fistulas with high intersphincteric extension**

R.S. van Onkelen, M.P. Gosselink and W.R. Schouten

*Diseases of the Colon and Rectum 2013;56:987-991*

## ABSTRACT

### Background

Intersphincteric fistulas with a high upward extension, up to or above the level of the puborectal muscle, in the intersphincteric plane are rare. Most of these fistulas have no external opening and they are frequently associated with a high intersphincteric and/or supralelevator abscess. Division of a large amount of internal anal sphincter by extended fistulotomy has a potential risk of diminished fecal continence. The aim of this study was to evaluate flap repair combined with drainage of associated abscesses in high intersphincteric fistulas.

### Method

Fourteen patients with a cryptoglandular fistula with high intersphincteric extension were included. Transanal advancement flap repair combined with intersphincteric and/or extrasphincteric drainage of associated abscesses was performed. Preoperatively, patients underwent endoanal MRI.

### Results

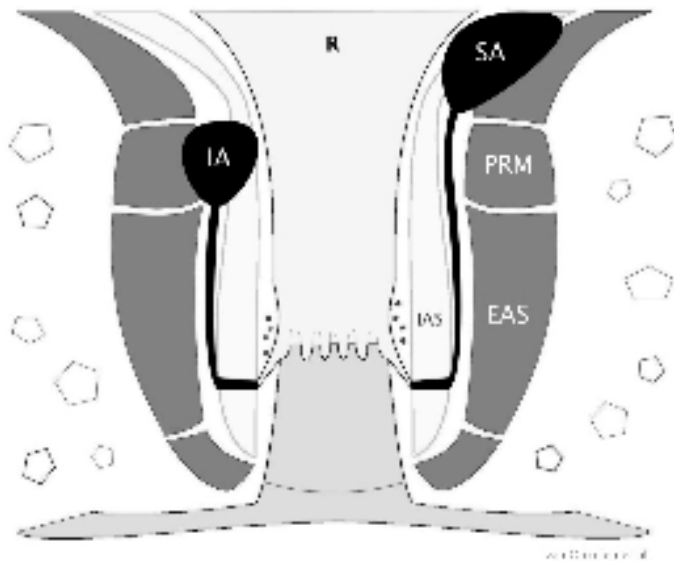
In 1 patient the fistula was not associated with an abscess. In 10 patients the fistula tract ended in a high intersphincteric abscess. Three patients presented with a high intersphincteric abscess and a supralelevator abscess. Primary healing was observed in 79% of the patients. The 3 patients without primary healing had a supralelevator abscess. In these patients, healing was obtained after a second, third, and fourth procedure. The overall healing rate was 100%. Median postoperative Rockwood score was 0 (range, 0-15).

### Conclusion

Since most high intersphincteric fistulas have no external opening and are frequently associated with abscesses, preoperative imaging is useful. Flap repair with adequate drainage of the abscesses is successful, except in fistulas with supralelevator extension. However, healing may be achieved by additional procedures.

## INTRODUCTION

In 1967, Parks et al<sup>1</sup> introduced a classification of anal fistulas based on the course of the fistula in relation to the anal sphincters. They defined 4 main types of fistulas, intersphincteric, transsphincteric, suprasphincteric, and extrasphincteric. Intersphincteric fistulas are the most common.<sup>1,2</sup> The majority of these fistulas have a short downward extension in the intersphincteric plane to their external opening near the anal verge and can be treated successfully by lay open fistulotomy.<sup>3,4</sup> In exceptional cases, intersphincteric fistulas lack an external opening and exhibit a high upward extension, up to or above the level of the puborectal muscle, in the intersphincteric plane and are frequently associated with a high intersphincteric and/or supralelevator abscess (Fig. 1).<sup>1</sup> To lay open these high intersphincteric fistulas adequately, division of a large amount of the internal anal sphincter is required,<sup>5-7</sup> with a potential risk of diminished fecal continence. To our knowledge no reports are available regarding sphincter-preserving alternatives for the treatment of high intersphincteric fistulas. The purpose of the present study was to evaluate whether these rare fistulas can be treated adequately by transanal advancement flap repair (TAFR) with subsequent drainage of associated abscesses.



**Figure 1.** Illustration of high intersphincteric fistulas

These fistulas have no external opening, extend upwards in the intersphincteric space, and end in a high intersphincteric and/or supralelevator abscess. R = rectum; PRM = puborectal muscle; EAS = external anal sphincter; IAS = internal anal sphincter; IA = intersphincteric abscess; SA = supralelevator abscess.

## METHOD

### Study design

Fourteen patients with a high intersphincteric fistula were selected from a database of 277 patients who underwent TAFR in our institution between March 1995 and February 2011. Patients with Crohn's disease were excluded from this study. Before the procedure, patients underwent endoanal MRI (EA MRI) to visualize the course of the fistula tract and to determine the presence and location of associated abscesses. All of the patients provided informed consent, meeting the standards set by the institutional review board of the hospital. All of the operations were performed by 1 surgeon (W.R.S.). Patients were treated in day-care setting.

### Endoanal MRI

All of the EA MRI examinations were performed with the use of an endoanal coil with a 1.5-T magnetic resonance imager (Gyrosan NT Intera 1.5, Philips Medical Systems, Best, the Netherlands). The endoanal coil (Philips Medical Systems) consisted of a fixed, rectangular, 60-mm—long rigid receiver coil with a width of 16 mm. In each patient, the following 3 sequences were used. Transverse T2-weighted, contrast-enhanced, fast field-echo imaging was performed. Transverse T2-weighted, fast spin echo MRI was performed with and without fat saturation. Coronal and sagittal T2-weighted spin echo MRI was performed without fat saturation. All of the EA MRIs were evaluated by 1 radiologist at our institution.

### Surgical techniques

#### *Transanal advancement flap repair*

Patients underwent complete mechanical bowel preparation (polyethylene glycol, Klean-Prep, Helsinn Birex Pharmaceuticals, Dublin, Ireland). After induction of general endotracheal anesthesia, metronidazole (500 mg), together with cefuroxime (1500 mg), was administered intravenously. The patient was placed in prone jackknife position with the buttocks taped apart. Initially a Park's retractor (Park's Anal Retractor, Slidell, LA ) was used to expose the internal opening of the fistula. Since 2003, a Lone Star retractor has been used for this purpose (Lone Star Retractor System, Lone Star Medical Products, Inc, Houston, TX). The internal opening was enlarged and the remaining crypt-bearing tissue was excised. A small rim of the anodermis, below the internal opening, was excised to create a neodentate line. The defect in the internal anal sphincter was closed with absorbable sutures 2/0 Vicryl (Ethicon, Inc, Somerville, NJ). A flap consisting of mucosa, submucosa, and some of the most superficial fibers of the internal anal sphincter was raised from the level of the dentate line and mobilized



over a distance of 4 to 6 cm proximally. The flap was advanced and sutured to the neodentate line with absorbable sutures 2/0 monocryl (Ethicon, Inc, Somerville, NJ).

### ***Intersphincteric drainage***

A curvilinear incision was made just outside the intersphincteric groove. Dissection was continued in the intersphincteric plane until the abscess was encountered. The tip of a mushroom drain (size 12 Fr (4 mm), Coloplast, Humlebaek, Denmark) was positioned within the abscess cavity. The drain was fixed at the perianal skin with nonabsorbable sutures (3/0 Ethilon, Ethicon, Inc, Norderstedt, Germany).

### ***Extrasphincteric drainage***

An incision was made in the posterior midline, a few centimeters from the anal verge. Dissection was continued into the deep postanal space. The supralelevator abscess cavity was entered through the pelvic floor muscle, and the tip of a mushroom drain (size 12 Fr (4 mm), Coloplast) was positioned in cavity. The drain was fixed at the perianal skin with nonabsorbable sutures (3/0 Ethilon, Ethicon, Inc, Norderstedt, Germany).

### **Postoperative care**

All of the patients were prescribed a stool softener for 2 weeks. There was no diet restriction. Patients were instructed to flush the drain 3 times per day until removal and to take a sitz bath 2 to 3 times daily until the wound was healed. After discharge, patients were advised to restrict physical activity for 2 weeks. The drain was removed during the first visit at outpatient clinic,  $\approx$ 2 weeks after surgery.

### **Data recording and follow-up**

Patient visits were scheduled 2 weeks, 8 weeks, and 6 months after surgery. Healing of the fistula was defined as complete wound healing with absence of symptoms. Patient and fistula characteristics were collected from medical charts. Follow-up information regarding fistula recurrence and fecal continence was obtained from medical charts and a follow-up telephone call. The postoperative fecal continence was assessed by using the Rockwood Fecal Incontinence Severity Index.

### **Statistical analysis**

Data were analyzed by use of SPSS-IBM software version 20.0 for Windows (SPSS Inc, Chicago, IL).

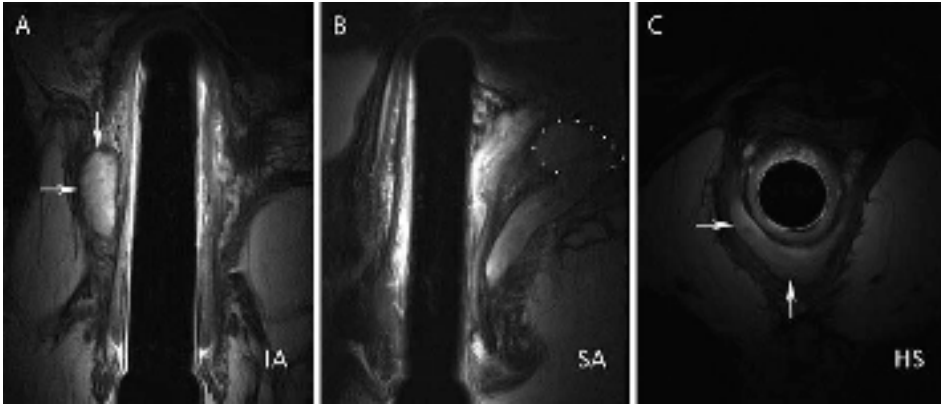
## RESULTS

The baseline patient and fistula characteristics are presented in Table 1. Nine patients (64%) had undergone  $\geq 1$  previous surgical attempt at repair before referral. Before TAFR, EA MRI was performed in all of the patients except 1, in whom this type of imaging was not possible because of the presence of a pacemaker. The high upward extension of the fistula tract and the presence of associated abscesses were confirmed during surgery in all 13 of the patients in whom EA MRI was performed. The internal opening of the fistula was located at the posterior midline in 13 patients. In 1 female patient the internal opening was located anteriorly. In all of the patients except 1, associated abscesses were identified. In 10 patients, the intersphincteric fistula tract ended in an abscess, located at the level of the puborectal muscle (Fig. 2A). The remaining 3 patients presented with both a high intersphincteric abscess and a satellite supralelevator abscess (Fig. 2B). In 6 patients, intersphincteric horseshoeing was identified (Fig. 2C). In only 2 of the 14 patients was an external fistula opening detected. In both cases this opening was located at the posterior midline, near the anal verge. Details of the surgical procedures and healing pattern are presented in Table 2. All of the patients underwent a TAFR. In 12 patients this procedure was performed with concomitant drainage of associated abscesses by an intersphincteric or an extrasphincteric approach. In 1 patient no abscess was identified, and in 1 patient the abscess was found to be dissolved during surgery. Primary healing was observed in 11 patients (79%). In the 3 patients without primary healing, the fistula was associated with a supralelevator abscess. In 1 patient with complete healing of

**Table 1.** Baseline patient and fistula characteristics

Baseline patient and fistula characteristics	n
Median age, years (range)	41 (26-71)
Sex ratio (male:female)	12:2
Previous surgical attempt at repair before referral	9
Preoperative seton drainage	2
Location of the internal opening	
Posterior	13
Anterior	1
Previous EA MRI	13
EA MRI	
IA	5
IA and HS	5
IA and SA	2
IA, SA and HS	1

EA = endoanal; IA = intersphincteric abscess; SA = supralelevator abscess; HS = horseshoeing.



**Figure 2.** Endoanal MRI of a high intersphincteric fistula with horseshoeing in the intersphincteric plane and associated high intersphincteric and supralelevator abscesses

A, The high intersphincteric abscess (IA; indicated by arrows) shows hyperintense signal on the sagittal T2-weighted spin echo (SE) image. B, The supralelevator abscess (SA; indicated by dots) shows hyperintense signal on the coronal T2 weighted SE image. C, The horseshoeing (HS; indicated by arrows) shows high signal intensity on the transverse T2-weighted fast SE image.

**Table 2.** Surgical management and healing

Surgical management and healing	Success (n)	Failure (n)
First intervention		
TAFR and IS drain (n = 10)	8	2
TAFR and ES drain (n = 2)	1	1
TAFR (n = 2)	2	0
Second intervention		
TAFR and IS drain (n = 1)	1	0
TAFR and ES drain (n = 1)	0	1
IS drain (n = 1)	0	1
Third intervention		
IS drain (n = 1)	0	1
ES drain (n = 1)	1	0
Fourth intervention		
IS and ES drain (n = 1)	1	0

TAFR = transanal advancement flap repair; IS = intersphincteric; ES = extrasphincteric.

the flap, second and third drainages were necessary to obtain healing. In 2 patients, a second TAFR with drainage was performed. This was successful in 1 patient. In the other patient the abscesses persisted, and third and fourth drainages were necessary to obtain healing. The overall healing rate was 100%. Median follow-up was 85.5 months (range, 20-211 months). None of the patients encountered incontinence for solid and/or liquid stool after their final treatment. However, in 6 patients minimal

postoperative incontinence to flatus and/or soiling was observed. None of the patients used pads. The median postoperative fecal continence score was 0 (range, 0-15).

## DISCUSSION

Most intersphincteric fistulas extend downward in the intersphincteric plane to the perianal skin. Their external opening is located close to the anal verge. Occasionally, intersphincteric fistulas extend upward, up to or above the level of the puborectal muscle.<sup>1</sup> These rare fistulas often lack an external opening and are frequently associated with intersphincteric and/or supralelevator abscesses (Fig. 1). Reviewing 400 patients with a perianal fistula, Parks et al<sup>1</sup> identified a high intersphincteric fistula in only 20 cases (5%). In the present study, 14 patients (5%) have been selected from a database of 277 patients who underwent a TAFR in our institution. The low incidence of these fistulas may be the reason that studies regarding their treatment are scarce. Lay open fistulotomy is the treatment of choice for patients with a simple intersphincteric fistula.<sup>3,4</sup> However, this procedure may not be appropriate for high intersphincteric fistulas. To lay open these fistulas sufficiently, division of a large amount of the internal anal sphincter is required. Although lay open fistulotomy of simple intersphincteric fistulas is considered a safe procedure, minor continence disturbances still occur, as reported by Toyonaga et al.<sup>8</sup> and Chang and Lin.<sup>9</sup> It seems likely that lay open fistulotomy in patients with a high intersphincteric fistula is associated with an increased risk of disturbed continence, because a larger portion of the internal anal sphincter must be divided. Therefore, a sphincter-preserving technique is preferred. Reviewing the literature, no data have been found regarding sphincter-preserving treatment of high intersphincteric fistulas. Therefore, we conducted the present study to assess the role of TAFR with concomitant drainage of associated abscesses in the treatment of these fistulas. The primary healing rate of 79% illustrates that flap repair combined with adequate drainage of associated abscesses is a good treatment option for patients with a high intersphincteric fistula. In the 3 patients without primary healing, a supralelevator abscess was present. This observation suggests that extension of the fistula tract to above the level of the pelvic floor prohibits primary healing after flap repair. However, in these patients healing may also be achieved by additional drainage. This resulted in an overall healing rate of 100%. None of the patients reported major incontinence after their final treatment. The median postoperative fecal continence score was 0 (range, 0-15). In several studies it has been demonstrated that preoperative imaging reveals essential information, especially in patients with a complex fistula.<sup>10-12</sup> In the present study, the external fistula opening was absent in 12 patients, and visible signs of associated abscesses were lacking. Although associated abscesses can be palpated

during surgical exploration in some cases, the exact location of these abscesses is very difficult to pinpoint by palpation alone. Since preoperative EA MRI revealed an associated abscess in 13 patients, we believe that appropriate preoperative imaging is helpful. In the present study, EA MRI provided essential information and guided the surgical procedure, especially regarding the approach of associated abscesses and the identification of intersphincteric horseshoe extension. Based on our experience, we recommend adequate preoperative imaging, which is useful for the correct diagnosis and appropriate treatment of fistulas with a high intersphincteric and/or supralelevator extension. The limitations of this study are the retrospective nature and the lack of data regarding preoperative fecal continence. Strengths of the study are the unique series of patients with a rare type of fistula, long median follow-up, and preoperative imaging in all of the patients. The present case series shows that preoperative imaging is useful in high intersphincteric fistulas. TAFR with concomitant drainage of associated abscesses is successful, except in the fistulas with a supralelevator extension. However, in these patients healing may also be achieved by additional drainage.

## REFERENCES

1. Parks AG, Gordon PH, Hardcastle JD. A classification of fistula-in-ano. *Br J Surg*. 1976;63:1-12.
2. Marks CG, Ritchie JK. Anal fistulas at St Mark's Hospital. *Br J Surg*. 1977;64:84-91.
3. Garcia-Aguilar J, Belmonte C, Wong WD, et al. Anal fistula surgery: factors associated with recurrence and incontinence. *Dis Colon Rectum*. 1996;39:723-729.
4. Steele SR, Kumar R, Feingold DL, et al; Standards Practice Task Force of the American Society of Colon and Rectal Surgeons. Practice parameters for the management of perianal abscess and fistula-in-ano. *Dis Colon Rectum*. 2011;54:1465-1474.
5. Parks AG, Thomson JP. Intersphincteric abscess. *Br Med J*. 1973;2:537-539.
6. Prasad ML, Read DR, Abcarian H. Supralelevator abscess: diagnosis and treatment. *Dis Colon Rectum*. 1981;24:456-461.
7. Bernard D, Tassé D, Morgan S. High intermuscular anal abscess and fistula: analysis of 25 cases. *Can J Surg*. 1983;26:136-139.
8. Toyonaga T, Matsushima M, Kiriu T, et al. Factors affecting continence after fistulotomy for intersphincteric fistula-in-ano. *Int J Colorectal Dis*. 2007;22:1071-1075.
9. Chang SC, Lin JK. Change in anal continence after surgery for intersphincteric anal fistula: a functional and manometric study. *Int J Colorectal Dis*. 2003;18:111-115.
10. Beets-Tan RG, Beets GL, van der Hoop AG, et al. Preoperative MR imaging of anal fistulas: Does it really help the surgeon? *Radiology*. 2001;218:75-84.
11. Scholefield JH, Berry DP, Armitage NC, et al. Magnetic resonance imaging in the management of fistula in ano. *Int J Colorectal Dis*. 1997;12:276-279.
12. Buchanan G, Halligan S, Williams A, et al. Effect of MRI on clinical outcome of recurrent fistula-in-ano. *Lancet*. 2002;360:1661-1662.







## Chapter 7

# Identification of epithelialization in high transsphincteric fistulas

L.E. Mitalas, R.S. van Onkelen, K. Monkhorst, D.D.E. Zimmerman, M.P. Gosselink and W.R. Schouten

*Techniques in Coloproctology 2012;16:113-117*

## ABSTRACT

### Background

At present, transanal advancement flap repair (TAFR) is the treatment of choice for transsphincteric fistulas passing through the upper and middle third of the external anal sphincter. It has been suggested that epithelialization of the fistula tract contributes to the failure of the treatment. The aim of this study was to assess the prevalence of epithelialization of the fistula tract and to study its effect on the outcome of TAFR and TAFR combined with ligation of the intersphincteric fistula tract (LIFT).

### Method

Forty-four patients with a high transsphincteric fistula of cryptoglandular origin underwent TAFR. Nine of these patients underwent a combined procedure of TAFR with LIFT. In all patients the fistula tract was excised from the external opening up to the outer border of the external anal sphincter. In patients undergoing TAFR combined with LIFT an additional central part of the intersphincteric fistula tract was excised. A total of 53 specimens were submitted. Histopathological examination of the specimens was carried out by a pathologist, blinded for clinical data.

### Results

Epithelialization of the distal and intersphincteric fistula tract was observed in only 25 and 22% of fistulas, respectively. There was no difference in outcome between fistulas with or without epithelialization.

### Conclusion

Epithelialization of high transsphincteric fistulas is rare and does not affect the outcome of TAFR and TAFR combined with LIFT.

## INTRODUCTION

The main objective in the treatment for fistulas, passing through the upper or middle third of the external anal sphincter, is healing of the fistula without subsequent damage to both sphincters. Although transanal advancement flap repair (TAFR) provides a useful tool for achieving this goal, fistula healing fails in one out of every three patients.<sup>1-8</sup> Several studies have been conducted to identify factors affecting the outcome of TAFR. However, until now, no definite factor predisposing to failure has been determined. In 1995, Lunniss et al.<sup>9</sup> observed epithelium lining the intersphincteric fistula tract in 13 out of 18 patients with a low perianal fistula. Though the effect of this epithelialization on fistula healing was not assessed, the authors stated that this might be a cause for the persistence of the fistula. This hypothesis is still generally accepted, and this study is cited in many papers and text books.<sup>10-13</sup> Recently Van Koperen et al.<sup>14</sup> also assessed the presence of epithelium in fistula tracts. In 18 patients with a low transsphincteric fistula they took biopsies at three different locations, on the side of the internal opening, in the middle of the fistula tract, and near the distal end close to the external opening. Epithelium was predominantly found near the internal opening. In the other parts of the fistula tract, epithelialization was found to be rare. According to these authors epithelialization might contribute to the failure of healing, although they did not provide evidence for this statement. The aim of the present study was to assess the prevalence of epithelialization of the fistula tract and to study the effect of epithelialization on the healing rate.

## METHOD

Between June 2008 and December 2009, 44 consecutive patients were enrolled in this study. The series comprised 30 men and 14 women. Median age at the time of repair was 46 years (range, 21-67 years). Median time interval since the onset of the fistula was 17 months (range, 5-73 months). Two patients underwent preoperative seton drainage for at least 2 months, until the day of the flap repair. Forty patients underwent a primary intervention, and 4 patients underwent secondary intervention after previous TAFR. In all patients the fistula tract crossed the upper or middle third of the external anal sphincter. All operations were performed by one surgeon (W.R.S.). Between June 2008 and January 2009, 35 patients underwent TAFR. In February 2009 ligation of the intersphincteric fistula tract (LIFT) was added to flap repair. In all patients the fistula tract was excised from the external opening up to the outer border of the external anal sphincter. In the nine patients who underwent a combined procedure,

the central part of the intersphincteric fistula tract was also harvested. A total of 53 specimens were submitted for histopathological examination.

### **Exclusion criteria**

Patients with a rectovaginal fistula or a fistula due to Crohn's disease were excluded from the present series.

### **Preoperative**

Patients underwent complete mechanical bowel preparation (polyethylene glycol: Klean-prep Helsinn Birex Pharmaceuticals, Dublin, Ireland). After induction of general endotracheal anesthesia, metronidazole (500 mg) together with cefuroxime (1,500 mg) was administered intravenously.

### **Operative technique TAFR**

After the patient was placed in the prone jackknife position, the external opening was enlarged. The fistula tract was excised as far as possible, up to the outer border of the external anal sphincter and submitted for histopathological examination. The internal opening of the fistula was exposed using a Lone Star retractor (Lone Star Retractor System, Lone Star Medical Products, Inc. Houston, TX, USA). The crypt-bearing tissue around the internal opening as well as the overlying anodermis was then excised. The fistula tract was cored out of the sphincters. The defect in the internal anal sphincter was closed with absorbable sutures. A flap consisting of mucosa, submucosa and some of the most superficial fibers of the internal anal sphincter was raised from the level of the dentate line and mobilized over a distance of 4 to 6 cm proximally. The flap was advanced and sutured to the neodentate line with absorbable sutures.

### **Operative technique LIFT**

With the patient in the prone jackknife position, a probe was introduced into the fistula tract. A curvilinear incision was made in the intersphincteric groove, and the fistula tract was identified with the probe in situ. Care was taken not to injure the anal sphincters. After the dissection of the fistula tract, the probe was removed. The intersphincteric fistula tract was ligated near the internal and external anal sphincters. The central part of the intersphincteric fistula tract was excised and submitted for histopathological examination. Finally, the wound in the intersphincteric groove was closed with non-absorbable sutures.

## Postoperative

All patients were immobilized for 5 days. All patients received a clear liquid diet for 5 days. During this time period, metronidazole and cefuroxime were administered intravenously three times daily.

## Histopathological examination

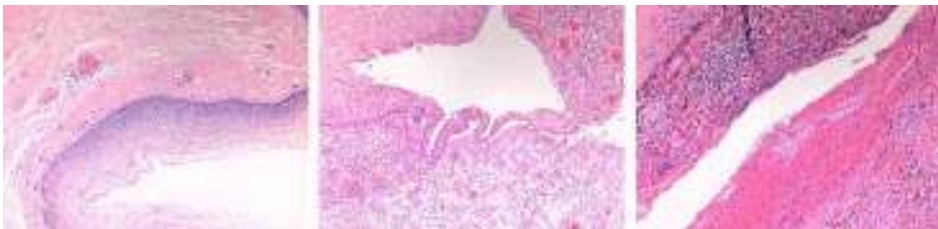After fixation in 10% formalin, the 53 specimens were cut in sections. These sections were stained using the routine hematoxylin and eosin staining method. Pan keratin antibodies were used for the detection of keratins, which are intermediate filament proteins expressed mainly in epithelial cells. The histopathological examination of the fistula tract was carried out by a pathologist, blinded for clinical data.

## Statistical analysis

Comparison of the changes between groups was conducted using the Fisher's exact probability test. The limit of statistical significance was set at  $P = 0.05$ .

## RESULTS

Median follow-up was 11 months (range, 6–13 months). The healing rate after surgery was 68%. In the fistula tracts extending from the external opening up to the outer border of the external anal sphincter, epithelialization was observed in 11 specimens (25%). In 5 of these patients the fistula tracts were completely lined with epithelium (Fig. 1), while in 6 patients the specimens were only partly lined with epithelium (Fig. 1). In the other specimens (75%) granulation tissue was observed (Fig. 1). In the intersphincteric fistula tract epithelium lining was observed in 2 specimens (22%). In both specimens the epithelial lining was complete. The fistula tract extending from the external opening up to the outer border of the external anal was also completely lined with epithelium in these 2 patients. In the other specimens (78%) the fistula tract was lined with granulation tissue. No anal gland tissue with mucin-producing cells could be detected in any of the patients. There was no difference in healing rate



**Figure 1.** From left to right, complete epithelial lining, incomplete epithelial lining and granulation tissue

**Table 1.** Overview of results based on presence or absence of epithelialization

	Epithelialization	No-epithelialization	P-value
Number of patients	11	33	
Age (years)	42	48	0.42
Gender (% male)	64	70	0.68
Time interval since onset	19	16	0.43
Healing rate (%)	64	70	0.55

between fistulas with or without epithelialization, as shown in Table 1. We found no correlation between either the time interval since onset of the fistula or prior seton drainage, and the presence of epithelium.

## DISCUSSION

Transanal advancement flap repair provides a useful tool for the treatment of high transsphincteric fistulas. Recent studies indicate that this procedure fails in one of the every three patients. Potential risk factors for failure, such as gender, age, body mass index, prior attempts at repair, rectal mucosal blood flow and previous use of a seton, have been analyzed.<sup>15,16</sup> Until now, no definite risk factor for failure has been identified. In the present study, similar healing rates were observed in patients with and those without epithelialization of their fistula tract. This finding indicates that epithelialization does not affect the outcome of TAFR and TAFR combined with LIFT. In 1995, Lunniss et al.<sup>9</sup> were the first to describe the epithelialization of perianal fistulas. They observed epithelium lining in 13 out of 18 patients. However, they did not mention whether the fistula tract was completely or partly lined with epithelium. Though the effect of epithelialization on fistula healing was not assessed, the authors stated that epithelialization might contribute to the persistence of fistulas. This hypothesis is still generally accepted, despite the lack of evidence.<sup>17,18</sup> Recently, Van Koperen et al.<sup>14</sup> examined the presence of epithelium in fistula tracts. In 18 patients with a low transsphincteric fistula they took biopsies from the fistula tract from 3 different locations, at the side of the internal opening, in the middle of the fistula tract, and near the distal end close to the external opening. At the side of the internal opening, epithelialization was observed in the majority of patients. In our opinion this epithelium does not represent epithelialization of the fistula tract since it is most likely derived from the epithelium lining of the crypts of Morgagni and the anal glands. Epithelialization was observed in 4 biopsies taken from the middle of the fistula tract and in only 2 biopsies taken from the distal end close to the external opening. These latter findings are almost similar to those obtained from the present study. Though epithelializa-

tion was observed almost exclusively near the internal opening and only a few fistula tracts were completely epithelialized, Van Koperen et al. stated that epithelialization of fistula tracts is present in most patients and might contribute to failure. In our opinion their study does not provide evidence for the adverse effect of epithelialization on fistula healing. Kiehne et al. compared squamous epithelium, obtained from perianal fistulas, with perianal skin and rectal mucosa. They found that the epithelial lining of fistulas expresses identical cytokeratins and similar levels of antimicrobial peptides as perianal skin. Based on this finding, they suggested that epithelialization of perianal fistulas starts at the side of the external opening and serves as a defense mechanism to prevent local and systemic infection by microbes from fecal material passing through the fistula tract.<sup>19</sup> According to these authors, epithelium growth in perianal fistulas is a late event. However, they did not assess the time interval between the onset of fistula development and the beginning of epithelialization. In the present study the median time interval since the onset of fistula development did not differ between patients with and without epithelial lining of their fistula. It is not known why epithelialization does not occur in every fistula at the same stage. It has been suggested that perpetuation of inflammation prevents the migration and arrangement of myofibroblasts, which are the key cells in the events of tissue repair.<sup>20</sup> These cells are able to form a new basement membrane, which is a prerequisite for the migration of epithelial cells. In the present study epithelialization of the distal and intersphincteric fistula tracts was found in only 25 and 22% of fistulas, respectively. The lack of epithelialization in the majority of our patients may be an expression of ongoing inflammation. Based on this assumption, one would expect a worse outcome after flap repair in patients without epithelialization of their fistula. However, in the present study similar healing rates were found in patients with and those without epithelial lining. Based on this observation, it seems obvious that epithelialization, like many other factors, does not adversely affect the outcome of flap repair. In a previous study we assessed the outcome of repeat flap repair in patients, who encountered a failure after the initial procedure. In all patients we noticed complete healing of the flap, except at the site of the original internal opening.<sup>21</sup> This remarkable finding does suggest that ongoing inflammation in the remaining fistula tract contributes to persistence of the fistula. Further studies are warranted to examine the microbiologic and immunologic characteristics of this inflammatory process.

## REFERENCES

1. Miller GV, Finan PJ. Flap advancement and core fistulectomy for complex rectal fistula. *Br J Surg.* 1998;85:108-110.
2. Mitalas LE, Gosselink MP, Oom DM, et al. Required length of follow-up after transanal advancement flap repair of high transsphincteric fistulas. *Colorectal Dis.* 2009;11:726-728.
3. Schouten WR, Zimmerman DDE, Briel JW. Transanal advancement flap repair of transsphincteric fistulas. *Dis Colon Rectum.* 1999;42:1419-1422.
4. Sonoda T, Hull T, Piedmonte MR, et al. Outcomes of primary repair of anorectal and rectovaginal fistulas using the endorectal advancement flap. *Dis Colon Rectum.* 2002;45:1622-1628.
5. Van der Hagen SJ, Baeten CG, Soeters PB, et al. Long-term outcome following mucosal advancement flap for high perianal fistulas and fistulotomy for low perianal fistulas: recurrent perianal fistulas: failure of treatment or recurrent patient disease? *Int J Colorectal Dis.* 2006;21:784-790.
6. Van der Hagen SJ, Baeten CG, Soeters PB, et al. Staged mucosal advancement flap for the treatment of complex anal fistulas: pretreatment with noncutting Setons and in case of recurrent multiple abscesses a diverting stoma. *Colorectal Dis.* 2005;7:513-518.
7. Zimmerman DDE, Delemarre JBVM, Gosselink MP, et al. Smoking affects the outcome of transanal mucosal advancement flap repair of transsphincteric fistulas. *Br J Surg.* 2003;90:351-354.
8. Mizrahi N, Wexner SD, Zmora O, et al. Endorectal advancement flap: are there predictors of failure? *Dis Colon Rectum.* 2002;45:1616-1621.
9. Lunniss PJ, Sheffield JP, Talbot IC, et al. Persistence of idiopathic anal fistula may be related to epithelialization. *Br J Surg.* 1995;82:32-33.
10. Buchanan GN, Sibbons P, Osborn M, et al. Experimental model of fistula-in-ano. *Dis Colon Rectum.* 2005;48:353-358.
11. Jun SH, Choi GS. Anocutaneous advancement flap closure of high anal fistulas. *Br J Surg.* 1999;86:490-492.
12. Williams JG, Farrands PA, Williams AB, et al. The treatment of anal fistula: ACPGBI position statement. *Colorectal Dis.* 2007;9:18-50.
13. Safar B, Jobanputra S, Sands D, et al. Anal fistula plug: initial experience and outcomes. *Dis Colon Rectum.* 2009;52:248-252.
14. Van Koperen PJ, Ten Kate FJW, Bemelman WA, et al. Histological identification of epithelium in perianal fistulae: a prospective study. *Colorectal Dis.* 2010;12:891-895.
15. Mitalas LE, Schouten SB, Gosselink MP, et al. Does rectal blood flow affect the outcome of transanal advancement repair? *Dis Colon Rectum.* 2009;52:1395-1399.
16. Mitalas LE, van Wijk JJ, Gosselink MP, et al. Seton drainage prior to transanal advancement flap repair: useful or not? *Int J Colorectal Dis.* 2010;25:1499-1502.
17. Rojanasakul A. Comments to the invited comment "LIFT procedure: a simplified technique for fistula in ano". *Tech Coloproctol.* 2010;14:53-54.
18. Sileri P, Franceschilli L, Angelucci GP, et al. Ligation of the intersphincteric fistula tract (LIFT) to treat anal fistula: early results from a prospective observational study. *Tech Coloproctol.* 2011;15:413-416.
19. Kiehne K, Fincke A, Brunke G, et al. Antimicrobial peptides in chronic anal fistula epithelium. *Scand J Gastroenterol.* 2007;42:1063-1069.
20. Bataille F, Rohrmeier C, Bates R, et al. Evidence for a role of epithelial mesenchymal transition during pathogenesis of fistulae in Crohn's disease. *Inflamm Bowel Dis.* 2008;14:1514-1527.



21. Mitalas LE, Gosselink MP, Zimmerman DDE, et al. Repeat transanal advancement flap repair: impact on the overall healing rate of high transsphincteric fistulas and on fecal continence. *Dis Colon Rectum*. 2007;50:1508-1511.



## Chapter 8

# **Assessment of microbiota and peptidoglycan in perianal fistulas**

R.S. van Onkelen, L.E. Mitalas, M.P. Gosselink, A. van Belkum, J.D. Laman and  
W.R. Schouten

*Diagnostic Microbiology and Infectious Disease 2013;75:50-54*

## ABSTRACT

### Background

Transanal advancement flap repair has been advocated as the treatment of choice for high transsphincteric perianal fistulas, but fails in 1 of every 3 patients. Persistence of the fistula after flap repair might be the result of ongoing disease in the remaining fistula tract.

### Method

In 10 specimens of the distal part of the fistula, microbiota was assessed by means of conventional microbiological culture and 16S rRNA gene sequencing. Pro-inflammatory bacterial peptidoglycan and recognition proteins were assessed by immunohistochemistry.

### Results

Bacterial species were bowel derived, skin derived, or a combination of both. No mycobacterium species were identified. 16S rRNA gene sequencing failed to identify bacteria in all but 1 specimen, most likely as a result of low numbers of organisms. Peptidoglycan was detected in 90% of the patients, and a host response to peptidoglycan in 60%.

### Conclusion

We suggest that peptidoglycan might play a role in the ongoing inflammation in perianal fistulas.

## INTRODUCTION

Transsphincteric fistulas passing through the lower third of the external sphincter can be easily treated by either classic laying open (fistulotomy) or excision (fistulectomy). These procedures provide excellent healing rates and a minimal risk of postoperative incontinence.<sup>1</sup> However, transsphincteric fistulas passing through the upper or middle third of the external anal sphincter are a notorious condition. Fistulotomy or fistulectomy will result in unacceptable continence disturbances in these cases. Therefore, sphincter-saving techniques have been developed. Despite new treatment modalities such as application of fibrin glue or the use of an anal fistula plug, transanal advancement flap repair (TAFR) remains the treatment of choice for patients with high transsphincteric fistulas.<sup>2</sup> This procedure is successful in 2 of every 3 patients.<sup>3</sup> Until now no definite factor predisposing to failure has been identified. A previous study conducted in patients with a persistent fistula after TAFR revealed complete healing of the flap, except at the site of the original internal opening.<sup>4</sup> This observation and the lack of factors predisposing to failure suggest that persistence of the fistula is caused by ongoing disease in the remaining fistulous tract. Inflammation seems to be an important part of the pathogenesis of perianal fistulas. A recent study, conducted in our hospital, revealed that most perianal fistulas are lined with granulation tissue.<sup>5</sup> The presence of granulation tissue in the fistulous tract is suggestive of an inflammatory process. Some authors studied the bacteriology of perianal fistulas of cryptoglandular origin.<sup>6,7,8</sup> Their reports failed to demonstrate pathogenic bacteria. Moreover, only low numbers of organisms were found, suggesting that permanent infection is not a major contributing factor to the persistence of perianal fistulas. However, these data were obtained only with the use of conventional culture techniques. These cultures require viability of the bacteria for which accurate handling of the clinical material is essential. It might be that bacteria died due to inadequate sample processing. Furthermore, conventional culture techniques are largely dependent on the type and range of media used. Modern molecular techniques that target bacterial 16S rRNA offer alternative and more sensitive means for the study of bacterial flora.<sup>9,10</sup> For this technique, the viability of strains is not required and even dead bacterial species can still be reliably identified. Live bacteria as well as inflammatory bacterial remnants could potentially contribute to the ongoing inflammation in the remaining fistula tract. Studies on the pathogenesis of different chronic inflammatory diseases, such as Crohn's disease, show that peptidoglycan (PG) is a powerful effector stimulating inflammation.<sup>11,12</sup> PG is a major component of the Gram-positive and Gram-negative bacterial cell wall, providing structural strength and allowing bacteria to resist osmotic pressure. Presence of PG in tissues and intracellularly in phagocytes can be assessed by immunohistochemical analysis, using monoclonal antibodies. The aim of this pilot

study was to address the hypothesis of chronic infection and bacterial remnants in persisting perianal fistulas by assessing the presence of bacteria in the fistula tract by means of 16S rRNA gene sequencing and pro-inflammatory bacterial PG detection. Furthermore, perianal fistulas were studied in situ for a host response to PG.

## METHOD

A consecutive series of 10 patients with a cryptoglandular transsphincteric fistula passing through the upper or middle third of the external anal sphincter underwent TAFR. None of the patients used metronidazole and/or antibiotics prior to surgery. Forty percent of the patients had had previous surgical attempts. The present series comprised 8 males and 2 females. None of the patients had hepatitis B and/or HIV at the time of the study. Median age at time of repair was 48 years (range 28-56). The healing rate was 60. Clinical data are presented in Table 1. All patients provided informed consent meeting the standards set by the hospital's institutional review board.

### Exclusion criteria

Patients with a rectovaginal fistula or a fistula related to Crohn's disease were excluded from the present series.

### Excision of the sample

With the patient in prone jack-knife position, the external opening was enlarged and the distal part of the fistula tract was excised as far as possible towards the outer border of the external anal sphincter. The outmost part of this tract was removed. The remaining fistula tract, containing the central part, was divided into 2 parts, of which 1 was immediately stored in an anaerobic container and processed within 2 h. The second part was cryopreserved in liquid nitrogen and stored at  $-80^{\circ}\text{C}$  for processing. After the excision of the fistulous tract, metronidazole (500 mg) together with cefuroxime (1500 mg) was administered intravenously and a TAFR was performed according to the previously described technique. A single surgeon performed all the procedures (WRS).

### Conventional microbiology

The samples were immersed in liquid growth media (including aerobic and anaerobic blood culture bottles) and were subjected to standard aerobic and anaerobic culture using various culture media including blood, McConkey, and Sauboraud agar plates in a routine and certified academic microbiological laboratory. After incubation, the media were examined by an experienced clinical microbiologist and pure cultures were

**Table 1.** Clinical data

Subject	Gender	Age (years)	Internal opening fistula	External opening fistula	Outcome surgery
1	M	43	Anterior medial	Right anterior lateral	Success
2	M	54	Posterior medial	Right Lateral	Success
3	M	56	Posterior medial	Right Lateral	Success
4	F	31	Posterior medial	Right Lateral	Success
5	M	28	Posterior medial	Posterior medial	Failure
6	M	55	Anterior medial	Left anterior lateral	Failure
7	M	45	Posterior medial	Posterior medial	Failure
8	F	52	Anterior medial	Left anterior medial	Success
9	M	47	Anterior medial	Right posterior medial	Success
10	M	49	Posterior medial	Left posterior medial	Failure

identified. In case of such pure cultures, the strains involved were stored for future use. In case of mixed cultures, the biomaterial was collected from the plate and stored in glycerol containing media for later use. After presumptive identification, pure cultures were analysed for precise species nature using Vitek technology and the API identification system. Vitek 2 (BioMérieux, Hazelwood, MO, USA) is a fully automated commercial microbial identification system. Culture for mycobacteria was performed using the MGIT960/BACTEC system (Becton Dickinson, Sparks, MD, USA).

### 16S rRNA sequencing

DNA extraction from the surgical material was piloted using a variety of methods. Employing small aliquots of an initial specimen, the optimal procedure was defined on the basis of DNA yield. Once the final protocol was established all specimens were treated similarly. DNA extracted from biopsies was amplified using general primers for the bacterial 16S rRNA genes. This involved broad-spectrum amplification of DNA from all bacterial species known and generated a mixture of polymerase chain reaction (PCR) products.

### Immunohistochemical analysis

The presence of PG in the excised fistula tract was assessed by immunohistochemical analysis using 2 monoclonal antibodies (mAb). Monoclonal antibody 2E9 (mouse IgG3) was generated by immunization with human gut-derived peptidoglycan, and mAb 15704 is a commercial anti-*S. aureus* PG IgG3 (QED Biosciences, San Diego, CA, USA). Monoclonal antibody 2E9 identifies cell wall fragments, the PG degradation product muramyl dipeptide, and lysozyme-solubilized cell walls of various Gram-positive bacteria. It is been suggested that 2E9 binds to the glycan backbone of PG.<sup>13</sup> Furthermore, it has been described that 2E9 binds to the cell wall of *S. epidermidis*. The commercial

mAb anti-*S. aureus* PG IgG3 mAb 15704 especially identifies the peptidoglycan of *S. aureus*, protein A-negative *S. aureus*, and *S. epidermidis*. The host response to PG was examined by immunostaining with monoclonal antibodies against 2 of the 4 PG recognition proteins (PGLYRP). We employed antibodies against PGLYRP1 (mAb 188C424) and antibodies against PGLYRP2 (mAb AAA4), which were raised against human serum amidase. The 4 human PG recognition proteins (PGLYRPs) are pattern recognition molecules that are conserved throughout evolution. For many pathogenic and nonpathogenic Gram-positive and Gram-negative bacteria, human PG recognition proteins are bacteria killing and bacteria inhibiting.<sup>14,15</sup> The immunohistochemistry methods for detection of intracellular PG have been previously described in detail.<sup>16,17</sup> In brief, frozen sections of 6 µm in thickness were fixed with freshly prepared acetone containing 0.02% of hydrogen peroxide to inhibit endogenous peroxidase activity for 10 min. Histochemical revelation of endogenous peroxidase with 4-chloro-1-naphthol was done first. Next, the sections were incubated overnight with primary antibodies at previously determined optimal dilutions at 4 °C. Secondary enzyme-labelled antibodies were applied and incubated at room temperature. Between incubations the slides were rinsed twice in phosphate-buffered saline/0.05% Tween 20. Histochemical revelation of alkaline phosphatase and horse radish peroxidase was done using Fast Blue BB base (blue reaction product; Sigma-Aldrich, St. Louis, MO, USA) and 3-amino 9-ethyl carbazole (AEC, Sigma-Aldrich, St. Louis, MO, USA). Finally, sections were counterstained in haematoxylin and mounted in Kaiser's glycerine gelatine with a cover slip. Sections of reactive human tonsils were used as internal positive control tissue. Staining controls were done by omission of the primary antibody and isotype-/subclass-matched negative control antibodies. To determine whether presence of PG is related to macrophage infiltration, sections of 3 patients were additionally stained for the presence of macrophages by acid phosphatase enzyme histochemistry. All sections were evaluated by 2 independent observers blinded to the staining protocol and tissue donor identity.

## RESULTS

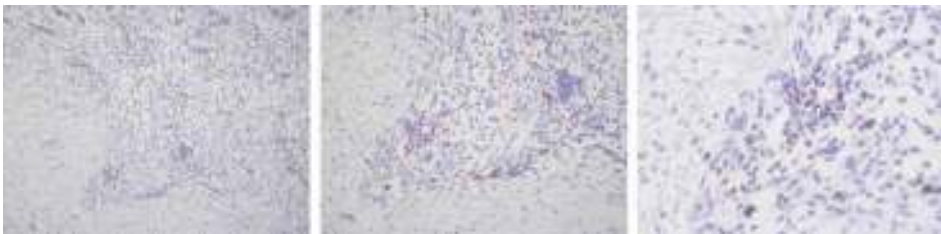
Clinical data are presented in Table 1. Aerobic or facultative organisms were isolated in 3 patients, anaerobic bacteria in 3 patients, and mixed aerobic and anaerobic microbiota in 3 patients (Table 2). In 1 patient, the culture was negative. The organisms, cultured from granulation tissue in the fistula tract, were bowel derived, skin derived, or a combination of both. No mycobacterium species were grown from any of the 10 patients. 16S rRNA sequencing used in the present study failed to identify bacteria in all but 1 patient (Table 2). In this patient, *Escherichia coli* was identified. Failure to detect



**Table 2.** Conventional microbiology and 16S rRNA sequencing of fistula tissue

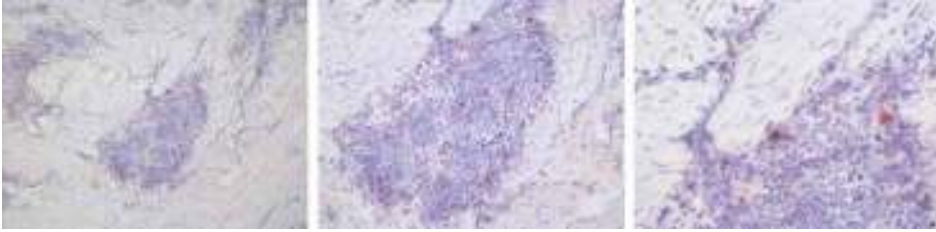Subject	Aerobic	Anaerobic	Mycobacteria	16S rRNA gene sequencing
1	Skinflora	Negative	Negative	Negative
2	Negative	E. coli	Negative	E. coli
3	Mixed flora	Mixed flora	Negative	Negative
4	Pantoea spp	Negative	Negative	Negative
5	Negative	Negative	Negative	Negative
6	Hemolytic streptococcus group C	Mixed flora	Negative	Negative
7	CNS group 1	Mixed flora	Negative	Negative
8	Negative	Mixed flora	Negative	Negative
9	S. aureus group 1 / Skinflora	Negative	Negative	Negative
10	Negative	Peptostreptococcus asaccharolyticus group 1	Negative	Negative

CNS = coagulase-negative staphylococcus.

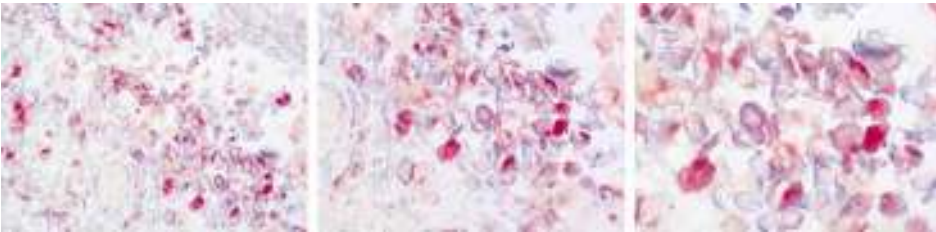


**Figure 1.** Peptidoglycan is present in cells within infiltrates of the fistula tissue. Presence of peptidoglycan (red) was detected by antibody 15704 directed against *S. aureus* PG. Magnifications are 10x, 20x, and 40x (from left to right).

bacteria in the other 9 patients was most likely caused by low numbers of organisms. Therefore, the culture-positive results were considered to be clinically insignificant. In contrast, immunohistochemical analysis revealed bacterial PG-containing cells (Fig. 1) and a host response to PG reflected by PGLYRP expression in the majority of patients (Fig. 2 and Table 3). Bacterial PG-containing cells were detected in 90% of the patients. Antibody 2E9 detected PG in 5 patients, while antibody 15704 raised against *S. aureus* PG identified PG in 9 patients. In 5 patients, both antibodies demonstrated the presence of PG. In all 3 patients with additional staining for macrophage infiltration, a high number of macrophages containing PG were shown (Fig. 3). In 6 patients, a host response to PG was detected by immunostaining with antibodies against PG recognition proteins, PGLYRP1 (188C424) and PGLYRP2 (mAb AAA4). PGLYRP1 was detected in 6 patients and PGLYRP2 in 2 patients. In 2 patients, both antibodies against PGLYRPs identified a host response. In 6 patients, binding of mAb for both bacterial



**Figure 2.** The host response to peptidoglycan is reflected by PGLYRP2 expression. PGLYRP2 (red) was detected by the antibody AAA4. Magnifications are 10x, 20x, and 40x (from left to right).



**Figure 3.** Parts of PG-containing cells are macrophages. Infiltrating macrophages were demonstrated by enzyme histochemistry for acid phosphatase activity (bright red). PG was visualized in blue. An example of a double-positive cell is prominently present in the centre of the image. Infiltrates also contain abundant numbers of cells containing PG but lacking acid phosphatase activity. These may include neutrophils and dendritic cells. Magnifications are 400x, 630x, and 1000x (from left to right).

**Table 3.** Peptidoglycan and PGLYRPs in fistula tissue

Subject	Presence of peptidoglycan		Host response to peptidoglycan	
	mAb 2E9	mAb 15704	PGLYRP1	PGLYRP2
1	–	–	–	–
2	–	+	+	+
3	–	+	+	–
4	–	+	–	–
5	+	+	+	–
6	+	+	+	–
7	+	+	+	+
8	+	+	+	–
9	–	+	–	–
10	+	+	–	–

+ = positive staining results; – = negative staining results.

PG-containing cells and a host response to PG were identified. Of these 6 patients, 1 showed binding of all antibodies. In 1 patient, none of the antibodies generated a signal. There were no obvious exceptional clinical parameters in these 2 patients.

The outcome of surgery does not seem to be related to the results of conventional microbiology, 16S rRNA sequencing, or immunohistochemical analysis.

## DISCUSSION

This pilot study shows that, although the numbers of bacteria in high transsphincteric fistulas seem too low to contribute to the ongoing inflammation in the remaining fistula tract, pro-inflammatory peptidoglycan (PG) is readily detectable in the majority of the fistulas and hence may contribute to the ongoing inflammation. The organisms, cultured from granulation tissue obtained from the fistula tract, represented bowel-derived, skin-derived, or a combination of both microbiota types. It seems unlikely that permanent infection with these species contributes to the chronicity of perianal fistulas, since they were present in such small numbers that 16S rRNA sequencing could not detect them. In contrast, Immunohistochemical analysis revealed bacterial PG-containing cells and a host response to PG in the majority of patients. It is generally accepted that perianal fistulas are secondary to perianal abscesses. After incision and drainage of such an abscess, a fistula remains in about half of the patients.<sup>18,19</sup> It is not clear which factors contribute to the development of a chronic and persistent fistula. The microbiology of perianal abscesses has been well described.<sup>19-21</sup> The bacteria cultured from perianal abscesses include bowel-derived organisms, skin-derived organisms, or a combination of both. According to some authors, bowel-derived organisms are associated with subsequent occurrence of a fistula.<sup>19,20</sup> However, this finding could not be confirmed by others.<sup>22</sup> Three studies have been conducted to assess the microbiology of cryptoglandular perianal fistulas.<sup>6-8</sup> Seow-Choen et al.<sup>8</sup> were the first to show that the microbiota in perianal fistulas is similar to the microbiota of perianal abscesses. However, cultures of granulation tissue, obtained from perianal fistulas, yielded much smaller numbers of organisms in comparison with pus obtained from perianal abscesses. Furthermore, they were not able to detect pathogenic organisms. Similar findings have been reported by others.<sup>6,7</sup> The conventional culture techniques used in these studies have several drawbacks. First, they require rapid and accurate handling of the material to prevent bacterial death. Second, conventional culture techniques are largely dependent on the type and range of media used. Third, the majority of bacteria are not able to thrive in isolation.<sup>23</sup> Particularly, the isolation of anaerobic bacteria is problematic.<sup>24</sup> In the present study, conventional culture techniques as well as 16S rRNA gene sequencing were used. PCR has been developed to aid in the diagnosis of bacterial infection by detecting bacterial genetic material.<sup>10,25</sup> Unlike culture, most molecular assays are designed specifically for a single microbial species. This provides high sensitivity and specificity. However, multiple assays may be

required to screen for multiple organisms. Broad-range assays, based on ribosomal genes (rDNA), are designed to overcome this limitation. Bacterial rRNA contains motifs of highly conserved nucleotide sequences that are shared by all bacterial species, interspersed with variable regions that are genus- or species specific. The DNA sequences of the variable regions form the basis of the phylogenetic classification of microbes.<sup>26</sup> By using PCR primers that are targeted at conserved regions of rDNA, it is possible to design broad-range PCRs capable of detecting DNA from almost any bacterial species. Bacterial identification is based on nucleotide sequencing of the PCR product followed by comparison of this sequence with known sequences in GenBank or other databases.<sup>27,28</sup> In the present study, 16S rRNA gene sequencing failed to identify bacteria in all but 1 patient. This was most likely caused by a very low number of organisms. Therefore, it seems unlikely that the bacteria, cultured from granulation tissue, obtained from perianal fistulas contribute to the chronicity of these fistulas. To the author's knowledge, the present study is the first to describe PG in perianal fistulas. PG is a major component of the bacterial cell wall with muramyl dipeptide as the main degradation product. Both PG and muramyl dipeptide have potent pro-inflammatory properties. PG induces inflammasome NLRP3-mediated caspase-1 (interleukin-1 $\beta$  convertase) activation and thereby processing and secretion of the pro-inflammatory cytokine interleukin-1 $\beta$ .<sup>29,30</sup> The highly potent 'fever cytokine' interleukin-1 $\beta$  is able to stimulate the expression of pro-inflammatory genes and acts on various organs. Pro-inflammatory cytokines interleukin-1 $\beta$  and interleukin-8 (a neutrophil chemoattractant) are expressed in biopsies of perianal fistulas.<sup>31</sup> Interleukin-8 was strongly expressed in the biopsies taken from the proximal part of the fistula tract. Moreover, interleukin-1 $\beta$  was strongly expressed in the biopsies taken from the distal part of the fistula tract. This could be relevant to our finding of bacterial PG-containing cells and a host response to PG in the distal part of the fistula tract. This suggests that PG may stimulate the secretion of interleukin-1 $\beta$  in perianal fistulas and might play an essential role in the ongoing inflammation in perianal fistulas. The outcome of surgery does not seem to be related to the results of conventional microbiology, 16S rRNA sequencing, or immunohistochemical analysis. As this is a pilot study, the number of patients is small. We are aware of this limitation and we are currently preparing a larger study on the presence of PG in different parts of perianal fistulas. This would also allow to further pursue questions on the identity of phagocyte subsets containing PG in addition to macrophages, such as dendritic cells and neutrophils, and on the direct relations between PG presence and local production of inflammatory mediators including interleukin-1.

## Conclusion

This pilot study demonstrates a paucity of bacteria in the fistula tract. Therefore, it seems unlikely that bacterial infection plays a major role in maintaining the fistulous disease. In contrast, we detected pro-inflammatory PG and a host response to PG in the majority of patients. We suggest that PG stimulates the secretion of interleukin-1 $\beta$  and other inflammatory mediators in perianal fistulas and might play an essential role in the ongoing inflammation.

## REFERENCES

1. van der Hagen SJ, Baeten CG, Soeters PB, et al. Long-term outcome following mucosal advancement flap for high perianal fistulas and fistulotomy for low perianal fistulas: recurrent perianal fistulas: failure of treatment or recurrent patient disease? *Int J Colorectal Dis.* 2006;21:784-790.
2. Williams JG, et al. The treatment of anal fistula: ACPGBI position statement. *Colorectal Dis.* 2007;9:18-50.
3. Mitalas LE, Gosselink MP, Oom DMJ, et al. Required length of follow-up after transanal advancement flap repair of high transsphincteric fistulas. *Colorectal Dis.* 2008;11:726-728.
4. Mitalas LE, Gosselink MP, Zimmerman DDE, et al. Repeat transanal advancement flap repair: impact on the overall healing rate of high transsphincteric fistulas and on fecal continence. *Dis Colon Rectum.* 2007;50:1508-1511.
5. Mitalas LE, van Onkelen RS, Monkhorst K, et al. Identification of epithelialization in high transsphincteric fistulas. *Tech Coloproctol.* 2012;16:113-117.
6. de San Ildefonso Pereira A, Maruri Chimeno I, Facal Alvarez C, et al. Bacteriology of anal fistulae. *Rev Esp Enferm Dig.* 2002;94:533-536.
7. Lunniss PJ, Faris B, Rees HC, et al. Histological and microbiological assessment of the role of microorganisms in chronic anal fistula. *Br J Surg.* 1993;80:1072.
8. Seow-Choen F, Hay AJ, Heard S, et al. Bacteriology of anal fistulae. *Br J Surg.* 1992;79:27-28.
9. Eckburg PB, et al. Diversity of the human intestinal microbial flora. *Science.* 2005;308:1635-1658.
10. Harris KA, Hartley JC. Development of broad-range 16S rDNA PCR for use in the routine diagnostic clinical microbiology service. *J Med Microbiol.* 2003;52:685-691.
11. Inohara N, et al. Host recognition of bacterial muramyl dipeptide mediated through NOD2. Implications for Crohn's disease. *J Biol Chem.* 2003;278:5509-5512.
12. Laman JD, Schoneveld AH, Moll FL, et al. Significance of peptidoglycan, a proinflammatory bacterial antigen in atherosclerotic arteries and its association with vulnerable plaques. *Am J Cardiol.* 2002;90:119-123.
13. Kool J, et al. Detection of intestinal flora-derived bacterial antigen complexes in splenic macrophages of rats. *J Histochem Cytochem.* 1994;42:1435-1441.
14. Tydell CC, Yount N, Tran D, et al. Isolation, characterization, and antimicrobial properties of bovine oligosaccharide-binding protein. A microbicidal granule protein of eosinophils and neutrophils. *J Biol Chem.* 2002;277:19658-19664.
15. Wang M, et al. Human peptidoglycan recognition proteins require zinc to kill both Gram-positive and Gram-negative bacteria and are synergistic with antibacterial peptides. *J Immunol.* 2007;178:3116-3125.
16. Melief MJ, Hoijer MA, Van Paassen HC, et al. Presence of bacterial floraderived antigen in synovial tissue macrophages and dendritic cells. *Br J Rheumatol.* 1995;34:1112-1116.
17. Schrijver IA, Melief MJ, Tak PP, et al. Antigen-presenting cells containing bacterial peptidoglycan in synovial tissues of rheumatoid arthritis patients coexpress costimulatory molecules and cytokines. *Arthritis Rheum.* 2000;43:2160-2168.
18. Schouten WR, van Vroonhoven TJMV. Treatment of anorectal abscess with or without primary fistulectomy. Results of a prospective randomized trial. *Dis Colon Rectum.* 1991;34:60-63.
19. Whitehead SM, Leach RD, Eykyn SJ, et al. The aetiology of perirectal sepsis. *Br J Surg.* 1982;69:166-168.

20. Grace RH, Harper IA, Thompson RG. Anorectal sepsis: microbiology in relation to fistula-in-ano. *Br J Surg*. 1982;69:401-403.
21. Toyonaga T, et al. Microbiological analysis and endoanal ultrasonography for diagnosis of anal fistula in acute anorectal sepsis. *Int J Colorectal Dis*. 2007;22:209-213.
22. Lunniss PJ, Phillips RKS. Surgical assessment of acute anorectal sepsis is a better predictor of fistula than microbiological analysis. *Br J Surg*. 1994;81:368-369.
23. Bowler PG, Duerden BI, Armstrong DG. Wound microbiology and associated approaches to wound management. *Clin Microbiol Rev*. 2001;14:244-269.
24. Davies CE, et al. Use of molecular techniques to study microbial diversity in the skin: chronic wounds reevaluated. *Wound Repair Regen*. 2001;9:332-340.
25. Fredricks DN, Relman DA. Application of polymerase chain reaction to the diagnosis of infectious diseases. *Clin Infect Dis*. 1999;29:475-486.
26. Doolittle WF. Phylogenetic classification and the universal tree. *Science*. 1999;284:2124-2429.
27. Drancourt M, Bollet C, Carlioz A, et al. 16S ribosomal DNA sequence analysis of a large collection of environmental and clinical unidentifiable bacterial isolates. *J Clin Microbiol*. 2000;38:3623-3630.
28. Janda JM, Abbott SL. Bacterial identification for publication: when is enough enough? *J Clin Microbiol*. 2002;40:1887-1891.
29. Martinon F, Agostini L, Meylan E, et al. Identification of bacterial muramyl dipeptide as activator of the NALP3/cryopyrin inflammasome. *Curr Biol*. 2004;14:1929-1934.
30. van de Veerdonk FL, Netea MG, Dinarello CA, et al. Inflammasome activation and IL-1beta and IL-18 processing during infection. *Trends Immunol*. 2011;32:110-116.
31. Kiehne K, Fincke A, Brunke G, et al. Antimicrobial peptides in chronic anal fistula epithelium. *Scand J Gastroenterol*. 2007;42:1063-1069.





## Chapter 9

# **Pro-inflammatory cytokines in anal fistulae**

R.S. van Onkelen, M.P. Gosselink, M. van Meurs, M.J. Melief, W.R. Schouten and  
J.D. Laman

*Submitted to Colorectal Disease*

## ABSTRACT

### Background

Sphincter preserving procedures for the treatment of transsphincteric fistulae fail in one out of every three patients. It has been suggested that failure is due to ongoing disease in the remaining fistula tract. Cytokines play an important role in inflammation. At present biologicals targeting cytokines are available. Therefore, detection and identification of cytokines in anal fistulae might have implications for future treatment modalities. The objective of the present study was to assess local production of a selected panel of cytokines in anal fistulae, including pro-inflammatory interleukin (IL)-1 $\beta$  and tumor necrosis factor  $\alpha$  (TNF- $\alpha$ ).

### Method

Fistula tract tissue was obtained from 27 patients with a transsphincteric fistula of cryptoglandular origin who underwent flap repair, ligation of the intersphincteric fistula tract (LIFT), or a combination of both procedures. Patients with a rectovaginal fistula or a fistula due to Crohn's disease were excluded. Frozen tissue samples were sectioned and stained using advanced immuno-enzyme staining methods for detection of selected cytokines, IL-1 $\beta$ , IL-8, IL-10, IL-12p40, IL-17A, IL-18, IL-36 and TNF- $\alpha$ . Presence and frequencies of cytokine-producing cells in samples were quantitated.

### Results

The key finding was abundant expression of IL-1 $\beta$  in 93% of the anal fistulae. Frequencies of IL-1 $\beta$  producing cells were highest (>50 positive stained cells) in 7% of the anal fistulae. Also, cytokines IL-8, IL-12p40 and TNF- $\alpha$  were present in respectively 70%, 33% and 30% of the anal fistulae.

### Conclusion

IL-1 $\beta$  is expressed in the large majority of cryptoglandular anal fistulae, as well as several other pro-inflammatory cytokines.

## INTRODUCTION

In a previous study, conducted in patients with a persistent anal fistula after flap repair, we observed complete healing of the flap, except at the site of the original internal fistula opening.<sup>1</sup> This observation and absence of factors predisposing to failure suggest that persistence of anal fistulae is caused by ongoing inflammation in the remaining fistula tract. A recent study, conducted at our institution, revealed that the majority of anal fistulae are lined with granulation tissue (75%), which is suggestive of an inflammatory response.<sup>2</sup> Since local bacterial replication might be an inflammatory factor we performed another study.<sup>3</sup> A paucity of bacteria was observed in the fistula tracts. Bacterial species were bowel derived, skin derived, or a combination of both. No mycobacterium species were identified. Therefore, it seems unlikely that bacterial infection plays a major role in persistence of fistula after surgery. These results were recently confirmed by Tozer et al.<sup>4</sup> In the same study we detected pro-inflammatory peptidoglycan in the majority of anal fistulae.<sup>3</sup> Peptidoglycan is a major component of the bacterial cell wall of both Gram positive and Gram negative species, providing structural strength and allowing bacteria to resist osmotic pressure. Peptidoglycan has potent pro-inflammatory properties and stimulates processing and secretion of the cytokine IL-1 $\beta$ .<sup>5-6</sup> This suggests that even in the absence of local bacterial replication, bacterial components promote chronic inflammation. Studies on the pathogenesis of different chronic inflammatory diseases, such as Crohn's disease, show that peptidoglycan is a powerful effector stimulating inflammation.<sup>7,8</sup> Cytokines play an important role in inflammation. TNF- $\alpha$ , IL-1 $\beta$  and other cytokines promote inflammatory responses that cause many of the clinical problems associated with immune-mediated diseases, such as rheumatoid arthritis, hidradenitis suppurativa, ulcerative colitis and Crohn's disease.<sup>9-12</sup> Biologicals targeting cytokines, such as anti-TNF- $\alpha$  and IL-1 receptor antagonist, are used in various diseases and clinical trials.<sup>13</sup> An overview of these agents is presented in Table 1, focusing on cytokines addressed in the current study. The question is whether one of these agents might play a role as adjunct in the treatment of anal fistulae. The objective of the present observational study was to detect and to identify cytokines in anal fistulae of cryptoglandular origin.

## METHOD

### Study design

Anal fistula tissue was obtained from 27 patients with a transsphincteric fistula of cryptoglandular origin that underwent transanal advancement flap repair (TAFR), ligation of the intersphincteric fistula tract (LIFT) or a combination of both procedures

**Table 1.** A summary of cytokines assessed and therapeutic options

<b>Cytokine</b>	<b>Main functions</b>	<b>Therapeutic molecules (generic name of biological*)</b>	<b>Main (potential) clinical applications</b>
IL-1 $\beta$	Inflammatory response to infection. Mediates fever and promotes formation of acute phase proteins by the liver. Activation of T and B lymphocytes. Elevates adhesion molecules on endothelium. Induces other cytokines such as IL-6. Resembles TNF- $\alpha$ in its inflammatory properties.	Anakinra (IL-1 receptor antagonist); Rilonacept (IL-1 receptor fusion protein); Canakinumab (anti-IL- $\beta$ mab)	RA, CAPS such as Muckle Wells syndrome (MWS) and familial cold auto-inflammatory syndrome (FCAIS)
IL-8 alias CXCL8	Mediator of innate immune responses. Induces chemotaxis of T cells and neutrophilic granulocytes. Promotes phagocytosis and angiogenesis.	Limited	Spectrum of (auto)-inflammatory diseases
IL-10	Anti-inflammatory. Inhibits production of cytokines by many cell types. Inhibits activation and effector functions of T cells, monocytes and macrophages.	Limited, e.g. Tenovil (recombinant IL-10)	Spectrum of (auto)-inflammatory diseases
IL-12p40	Differentiation of naive T cells into T-helper 1 cells. Induction of IFN- $\gamma$ in NK cells and T cells. Growth factor for activated CD4+ and CD8+ T lymphocytes and NK cells, and enhancement of their function.	Ustekinumab (mab against shared p40 subunit of IL-12 and IL-23); Briakinumab ( mab against shared p40 subunit of IL-12 and IL-23)	Psoriasis, CD
IL-17A	Central to induction and maintenance of proinflammatory responses. Induces other inflammatory cytokines and mediators, notably chemoattractants including those for neutrophilic granulocytes. IL-17A is critical to function of the Th17 subset of CD4+ lymphocytes.	Secukinumab (mab against IL-17A); Ixekizumab (mab against IL-17A) Brodalumab (mab against IL-17 receptor)	Psoriasis, RA, AS, RRMS
IL-18 (IL-1 family)	Induces cell-mediated immunity to intracellular pathogens. Induces IFN- $\gamma$ , and other cytokines and chemokines.	Limited	Spectrum of (auto)-inflammatory diseases
IL-36 (IL-1 family)	Acts directly on naive T cells, enhancing proliferation and IL-2 production. Stimulates Th1 responses. Acts on dendritic cells. Appears to be especially expressed and functional in the skin.	Limited	Spectrum of (auto)-inflammatory diseases
TNF- $\alpha$	Participates in inflammation, wound healing, and remodelling of tissue. Induces apoptosis, other cytokines and inflammation. Facilitates leukocyte recruitment, induces angiogenesis, and promotes fibroblast proliferation. Induces expression of adhesion molecules on vascular endothelium.	Infliximab (anti-TNF mab); Adalimumab (anti-TNF mab); Golimumab (anti-TNF mab); Etanercept (soluble receptor for TNF) Certolizumab (anti-TNF mab)	RA, CD, UC, AS, PsA, JIA, Psoriasis, HS

\*Nomenclature of biologicals includes, -cept for receptor, -ki(n) for interleukin -mab for monoclonal antibody, -ra for receptor antagonist, -u for human, -zu for humanized. Abbreviations: AS, ankylosing spondylitis; CAPS, cryopyrin-associated periodic syndromes; CD, Crohn's disease; HS, hidradenitis suppurativa. IL, interleukin; JIA, juvenile idiopathic arthritis; mab, monoclonal antibody; NK, natural killer; PsA, psoriatic arthritis; RA, rheumatoid arthritis; RRMS, relapsing remitting multiple sclerosis; TNF, tumor necrosis factor; UC, ulcerative colitis.<sup>14-17</sup>

at the Division of Colon and Rectal Surgery, Erasmus MC, University Medical Center. Prior to the procedure patients underwent endoanal magnetic resonance imaging to visualize the course of the fistula tract and to determine the presence and location of associated abscesses. Patients with a rectovaginal fistula and/or a fistula due to Crohn's disease were excluded from this study. None of the patients had hepatitis B and/or HIV at the time of surgery. None of the patients used metronidazole and/or antibiotics prior to surgery. Baseline patient and fistula characteristics are presented in Table 2. All patients provided informed consent meeting the standards set by the hospital's Institutional Review Board. All operations were performed by one surgeon and several colorectal surgery fellows. Patients were treated in a day-care setting.

### Operative techniques

We described our techniques of TAFR and LIFT earlier in detail.<sup>18</sup>

### Sample collection

The external fistula opening was enlarged and the fistula tract was excised as far as possible until the outer border of the external anal sphincter. Immediately after excision the fistula tract was frozen using dry ice and transported to the laboratory

**Table 2.** Baseline patient and fistula characteristics (n = 27)

Patient and/or fistula characteristic	N
Age at surgery (years)	46.2 ± 10.5
Sex (male)	15 (55.6)
Fistula type	
HTS	22 (81.5)
LTS	5 (18.5)
Location internal fistula opening*	
Anterior	10 (37.0)
Posterior	15 (55.6)
Lateral	1 (3.7)
Location external fistula opening	
Anterior	0 (0)
Posterior	4 (14.8)
Lateral	23 (85.2)
Type of operative technique	
TAFR	13 (48.2)
LIFT	6 (22.2)
TAFR & LIFT	8 (29.6)

Categorical variables are presented as numbers (%). Continuous values are expressed as mean ± SD. Abbreviations: HTS, high transsphincteric fistula; LTS, low transsphincteric fistula; TAFR, transanal advancement flap repair; LIFT, ligation of intersphincteric fistula tract. \*The internal fistula opening was not identified in one patient.

for cryopreservation. Excised tissue was cryopreserved in liquid nitrogen and subsequently stored at  $-80^{\circ}\text{C}$  for processing. The value of samples from healthy controls or patients with other afflictions as reference groups has been considered. However, the only possibility to obtain healthy anal tissue (including anal glands) from patients is during major surgery of this specific part of the body. Indications for these types of surgery are Crohn's disease or colorectal cancer. These diseases would certainly bias any findings as they are associated with increased expression of cytokines.<sup>11,19</sup> Also the potential value of samples from deceased patients without colorectal diseases as reference groups has been considered. However, we reasoned that any cause of death and death itself might probably bias any findings. Therefore, we have decided to use no reference group.

### **In situ analysis of cytokine-producing cells**

Frozen tissue samples were sectioned and stained using advanced immuno-enzyme staining methods for detection of selected cytokines IL-1 $\beta$ , IL-8, IL-10, IL-12p40, IL-17A, IL-18, IL-36 and TNF- $\alpha$ . This selection of cytokines was designed based on current concepts of tissue inflammation versus inflammation control (e.g. IL-10), and the availability of clinically approved biologicals (see Table 1). In short, frozen sections of 6  $\mu\text{m}$  in thickness were dried overnight in a humidified box before getting fixed with freshly prepared acetone containing 0.02% of hydrogen peroxide to inhibit endogenous peroxidase activity by cells in the tissue (e.g. granulocytes) for 10 minutes. Histochemical revelation of endogenous peroxidase with 4-chloro-1-naphthol was performed resulting in a dense blue-black precipitate. After this the sections were incubated overnight with primary antibodies at previously determined optimal dilutions at  $4^{\circ}\text{C}$ . Respectively, the following commercially available antibodies were used anti-human IL-1 $\beta$  (clone 8516.31, R&D Systems, Minneapolis, MN), anti-human IL-8 (clone G265-8, BD Biosciences Pharmingen, San Jose, CA), anti-human IL-10 (clone JES3-12G8, BD Biosciences Pharmingen), anti-human IL-12p40 (clone C8.6, BD Biosciences Pharmingen), anti-human IL-17A (clone e B 1064 CAP, eBioscience, Inc., San Diego, CA), anti-human IL-18 (rabbit IgG, Thermo Scientific, Rockford, IL), anti-human IL-36 (clone 3A12, Abcam, Cambridge, MA) and anti-human TNF- $\alpha$  (clone 61E7, U-CyTech Biosciences, Utrecht, the Netherlands). Secondary enzyme-labelled antibodies were applied and incubated at room temperature. Between incubations the slides were rinsed twice in phosphate-buffered saline/0.05% Tween 20. Histochemical revelation of horseradish peroxidase activity was performed using amino ethyl carbazole (AEC, Sigma-Aldrich, St. Louis, MO) for a bright red translucent staining. Finally, sections were counterstained with haematoxylin and mounted in Kaiser's glycerine gelatine with a cover slip. Sections of reactive human tonsils were used as internal positive control tissue since they contain numerous leukocytes producing a variety of cytokines.

Staining controls were done by omission of the primary antibody and by isotype- and subclass-matched negative control antibodies.

### Quantitation of cytokine-producing cells

In order to interpret the presence and frequencies of cytokine-producing cells, the number of positive stained cells in the fistula samples were scored from zero to four. Respectively, zero for no stained cells, one for 1 to 5 stained cells, two for 6 to 20 stained cells, three for 21 to 50 stained cells and four for >50 stained cells. All sections were evaluated by two independent observers.

### Statistical analysis

Continuous data are presented as mean values with standard deviation. Categorical data are presented as frequencies or percentages. Data were analysed by use of SPSS-IBM® software version 20.0 for Windows® (SPSS, Chicago, IL).

## RESULTS

Anal fistula samples were obtained from 27 patients with a transsphincteric fistula of cryptoglandular origin during surgery. Of these, 13 patients (48%) underwent flap repair, 6 patients (22%) underwent ligation of the intersphincteric fistula tract (LIFT) and 8 patients (30%) underwent a combination of both procedures. Baseline patient and fistula characteristics are presented in Table 2. Presence and frequencies of cytokine-producing cells in anal fistula samples were evaluated using a pathology scoring system. These findings are presented in Table 3. In the positive control tissue, reactive human tonsils from children, cells producing all cytokines were detected in

**Table 3.** Presence and frequencies of cytokine-producing cells in anal fistulae (n=27)

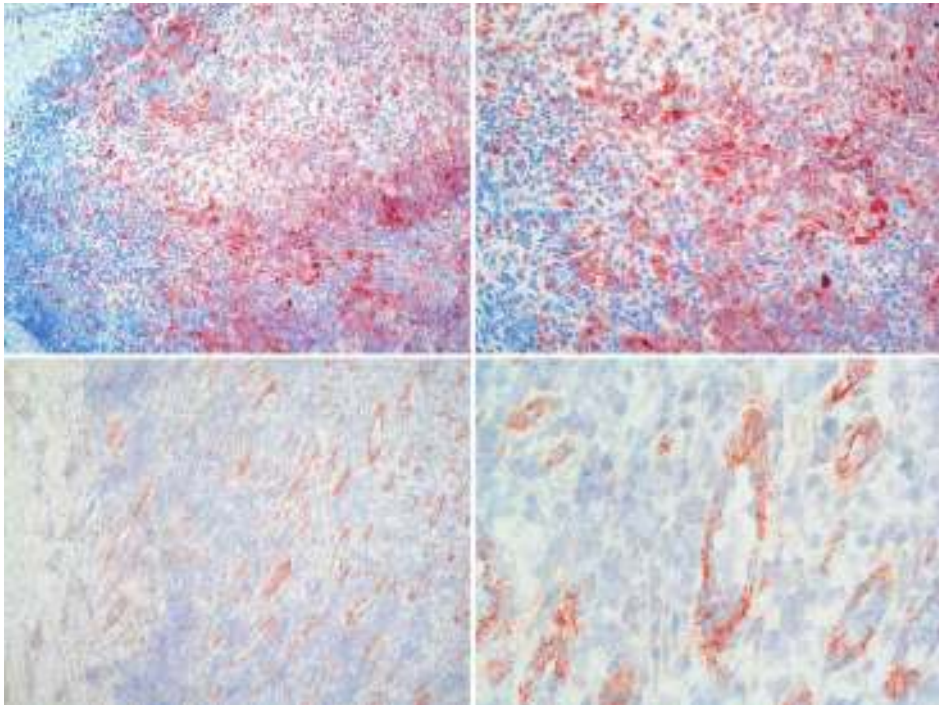
Cytokine	N (%)	No stained cells	1 to 5 stained cells	6 to 20 stained cells	21 to 50 stained cells	>50 stained cells
IL-1 $\beta$	25 (92.6)	2 (7.4)	4 (14.8)	12 (44.4)	7 (26.0)	2 (7.4)
IL-8	19 (70.4)	8 (29.7)	4 (14.8)	6 (22.2)	5 (18.5)	4 (14.8)
IL-10	0 (0)	27 (100)	0 (0)	0 (0)	0 (0)	0 (0)
IL-12p40	9 (33.3)	18 (66.7)	1 (3.7)	7 (25.9)	1 (3.7)	0 (0)
IL-17A	0 (0)	27 (100)	0 (0)	0 (0)	0 (0)	0 (0)
IL-18	0 (0)	27 (100)	0 (0)	0 (0)	0 (0)	0 (0)
IL-36	0 (0)	27 (100)	0 (0)	0 (0)	0 (0)	0 (0)
TNF- $\alpha$	8 (29.6)	19 (70.4)	3 (11.1)	4 (14.8)	1 (3.7)	0 (0)

Variables are presented as numbers (%). Abbreviations: IL, interleukin; TNF, tumor necrosis factor.

varying numbers, as predicted. This confirms the anticipated reactivity of the antibodies used and their suitability for detection of cytokines in frozen tissue. In 93% of the fistula samples the prominent pro-inflammatory cytokine IL-1 $\beta$  was present. Frequencies of IL-1 $\beta$  producing cells were highest (>50 positive stained cells) in 7% of the fistula samples (Fig 1). The cytokines IL-8, IL-12p40 and TNF- $\alpha$  were present in respectively 70%, 33% and 30% of the fistula samples (Fig 1). IL-10, IL-17A, IL-18 and IL-36 could not be detected.

## DISCUSSION

The key finding of the present study was the abundant expression of pro-inflammatory cytokine IL-1 $\beta$  in 93% of the anal fistulae. Also, the cytokines IL-8, IL-12p40 and TNF- $\alpha$  were expressed in a high number of anal fistulae (Table 3). Limitations of this study are the lack of a control or reference group and a potential selection bias caused



**Figure 1.** IL-1 $\beta$  and IL-8 in anal fistula samples  
IL-1 $\beta$  and IL-8 are expressed by cells within infiltrates of the anal fistula tissue. Presence of IL-1 $\beta$  (red) and IL-8 (red) was detected by specific antibodies. IL-1 $\beta$  is presented in the two upper images and magnifications are 100x and 200x (from left to right). IL-8 is presented in the two lower images and magnifications are 100x and 400x (from left to right).



by the status of our institution as tertiary referral center. Strengths of the study are the large number of patients, the comprehensive panel of cytokines studied, and the homogeneity of the patient group. IL-1 is a central mediator of innate immunity, inflammation and fever. As a highly active pro-inflammatory cytokine it contributes to lowering pain thresholds and to tissue damage. IL-1 $\beta$  can be produced by many different cell types, with a prominent role of monocytes and macrophages.<sup>20</sup> The stimulus can be microbial products, cytokines and even IL-1 $\beta$  itself.<sup>21</sup> Self-induction by IL-1 is part of the mechanism of auto-inflammation.<sup>12</sup> The IL-1 $\beta$  precursor is inactive within the cell and biologically active IL-1 $\beta$  is produced by inflammasomes that cleave pro-IL-1 $\beta$  using caspase-1. Based on our previous study, it seems likely that peptidoglycan is a one of the potential stimuli for the expression of IL-1 $\beta$  in anal fistulae. Peptidoglycan induces inflammasome NLRP3-mediated caspase-1 activation and thereby processing and secretion of IL-1 $\beta$ . This concept is supported by presence of peptidoglycan in 90% of cryptoglandular anal fistulae.<sup>3</sup> Self-induction by IL-1 may also be involved. Overall, our findings suggest that cytokines contribute to the inflammatory process in cryptoglandular anal fistulae. Flap repair has been advocated as the treatment of choice for high transsphincteric anal fistulae and enables healing in two of every three patients.<sup>22,23</sup> A pilot study by Verhagen et al. showed that flap repair with additional injection of platelet-rich plasma (PRP) in the anal fistula tract increases the healing rate to 90%.<sup>24</sup> A second study with a longer duration of follow-up confirmed these promising results.<sup>25</sup> According to the authors PRP improves wound healing and may therefore improve the closure rate of anal fistulae. PRP has also anti-inflammatory potentials. Kim et al. showed that PRP is able to suppress expression of degrading enzymes and mediators induced by TNF- $\alpha$  and IL-1 $\beta$ .<sup>26</sup> It seems likely that this mode of action also contributes to the higher healing rate after flap repair. Currently, three IL-1 antagonists (Anakinra, Rilonacept, and Canakinumab) targeting IL-1 $\beta$  are approved for treatment of various diseases (Table 1). Studies on IL-1 antagonists targeting a broad spectrum of new indications, such as hidradenitis suppurativa, show promising results.<sup>27</sup> In conclusion, pro-inflammatory IL-1 $\beta$  is expressed in the large majority of cryptoglandular anal fistulae and we propose that adjunct treatment of anal fistulae by targeting cytokines may potentially be beneficial. Further research on this matter is mandatory.

## REFERENCES

1. Mitalas LE, Gosselink MP, Zimmerman DDE, et al. Repeat transanal advancement flap repair: Impact on the overall healing rate of high transsphincteric fistulas and on fecal continence. *Dis Colon Rectum* 2007;50:1508-1511.
2. Mitalas LE, van Onkelen RS, Monkhorst K, et al. Identification of epithelialization in high transsphincteric fistulas. *Tech Coloproctol* 2012;16:113-117.
3. van Onkelen RS, Mitalas LE, Gosselink MP, et al. Assessment of microbiota and peptidoglycan in perianal fistulas. *Diagn Microbiol Infect Dis* 2013;75:50-54.
4. Tozer PJ, Rayment N, Hart AL, et al. What role do bacteria play in persisting fistula formation in idiopathic and Crohn's anal fistula? *Colorectal Dis* 2015;17:235-241.
5. Martinon F, Agostini L, Meylan E, et al. Identification of bacterial muramyl dipeptide as activator of the NALP3/cryopyrin inflammasome. *Curr Biol* 2004;14:1929-1934.
6. van de Veerdonk FL, Netea MG, Dinarello CA, et al. Inflammasome activation and IL-1 $\beta$  and IL-18 processing during infection. *Trends Immunol* 2011;32:110-116.
7. Inohara N, Ogura Y, Fontalba, et al. Host recognition of bacterial muramyl dipeptide mediated through NOD2. Implications for Crohn's disease. *J Biol Chem* 2003;278:5509-5512.
8. Laman JD, Schoneveld AH, Moll FL, et al. Significance of peptidoglycan, a proinflammatory bacterial antigen in atherosclerotic arteries and its association with vulnerable plaques. *Am J Cardiol* 2002;90:119-123.
9. Feldmann M. Development of anti-TNF therapy for rheumatoid arthritis. *Nat Rev Immunol* 2002;2:364-371.
10. Braegger CP, Nicholls S, Murch SH, et al. Tumour necrosis factor alpha in stool as a marker of intestinal inflammation. *Lancet* 1992;339:89-91.
11. Murch SH, Braegger CP, Walker-Smith JA, et al. Location of tumour necrosis factor alpha by immunohistochemistry in chronic inflammatory bowel disease. *Gut* 1993;34:1705-1709.
12. Dinarello CA, Simon A, van der Meer JWM. Treating inflammation by blocking interleukin-1 in a broad spectrum of diseases. *Nat Rev Drug Discov* 2012;11:633-652.
13. O'Shea JJ, Kanno Y, Chan AC. In search of magic bullets: The golden age of immunotherapeutics. *Cell* 2014;157:227-240.
14. Cruse JM, Lewis RE. *Illustrated dictionary of immunology*. (edn 3) CRC Press, London. 2009
15. Gaffen SL, Jain R, Garg AV, et al. The IL-23-IL-17 immune axis: From mechanisms to therapeutic testing. *Nat Rev Immunol* 2014;14:585-600.
16. Gresnigt MS, van de Veerdonk FL. Biology of IL-36 cytokines and their role in disease. *Semin Immunol* 2013;25:458-465.
17. Saxena A, Khosraviani S, Noel S, et al. Interleukin-10 paradox: A potent immunoregulatory cytokine that has been difficult to harness for immunotherapy. *Cytokine* Published Online First: 3 December 2014. doi:10.1016/j.cyto.2014.10.031.
18. van Onkelen RS, Gosselink MP, Schouten WR. Is it possible to improve the outcome of transanal advancement flap repair for high transsphincteric fistulas by additional ligation of the intersphincteric fistula tract? *Dis Colon Rectum* 2012;55:163-166.
19. Ning Y, Manegold PC, Hong YK, et al. Interleukin-8 is associated with proliferation, migration, angiogenesis and chemosensitivity in vitro and in vivo in colon cancer cell line models. *Int J Cancer* 2011;128:2038-2049.
20. Sims JE, Smith DE. The IL-1 family: Regulators of immunity. *Nat Rev Immunol* 2010;10:89-102.

21. Dinarello CA, Ikejima T, Warner SJ, et al. Interleukin 1 induces interleukin 1. I Induction of circulating interleukin 1 in rabbits in vivo and in human mononuclear cells in vitro. *J Immunol* 1987;139:1902-1910.
22. Schouten WR, Zimmerman DDE, Briel JW. Transanal advancement flap repair of transsphincteric fistulas. *Dis Colon Rectum* 1999;42:1419-1422.
23. van Koperen PJ, Bemelman WA, Gerhards MF, et al. The anal fistula plug treatment compared with the mucosal advancement flap for cryptoglandular high transsphincteric perianal fistula: A double-blinded multicenter randomized trial. *Dis Colon Rectum* 2011;54:387-393.
24. van der Hagen SJ, Baeten CG, Soeters PB, et al. Autologous platelet-derived growth factors (platelet-rich plasma) as an adjunct to mucosal advancement flap in high cryptoglandular perianal fistulae: a pilot study. *Colorectal Dis* 2011;13:215-218.
25. Göttgens KW, Vening W, van der Hagen SJ, et al. Long-term results of mucosal advancement flap combined with platelet-rich plasma for high cryptoglandular perianal fistulas. *Dis Colon Rectum* 2014;57:223-227.
26. Kim HJ, Yeom JS, Koh YG, et al. Anti-inflammatory effect of platelet-rich plasma on nucleus pulposus cells with response of TNF- $\alpha$  and IL-1. *J Orthop Res* 2014;32:551-556.
27. Leslie KS, Tripathi SV, Nguyen TV, et al. An open-label study of anakinra for the treatment of moderate to severe hidradenitis suppurativa. *J Am Acad Dermatol* 2014;70:243-251.



Chapter 10

# **Summary and general discussion**



Anal fistulas have been treated since the beginning of medicine and the classical treatment of anal fistulas is to surgically lay-open the fistula (fistulotomy). Although this treatment is highly effective for healing of anal fistulas, fistulotomy risks diminished fecal continence in patients with anal fistulas that require division of a large proportion of the anal sphincters. In modern colorectal surgery the main objective in treatment of anal fistulas is healing of the fistula without diminished fecal continence. Recent findings even indicate that for most patients it is more important to minimize their risk of diminished faecal continence than to have a highly successful treatment for their fistula.<sup>1</sup> Over time several sphincter preserving procedures have been developed for anal fistulas, such as transanal advancement flap repair (TAFR) and ligation of the intersphincteric fistula tract (LIFT). Although these sphincter preserving procedures are effective in preventing diminished fecal continence after surgery, they seem less effective for healing of anal fistulas than fistulotomy. The healing rate after TAFR varies between 60 and 70% and the healing rate after LIFT varies between 50 and 70%.<sup>2-11</sup> The reason for these rather disappointing results remains unclear and predictors of outcome have not been defined.

In this thesis, we first evaluated several sphincter preserving procedures for anal fistulas and factors that might affect the outcome of treatment. Anal fistulas have always been considered a surgical challenge and most studies have been conducted to optimize surgical treatment by evaluating and developing new techniques. However, healing rates remained disappointing and it seemed unlikely that surgical treatment will ever lead to fistula healing in all patients. This made us change our approach. We suggested that ongoing inflammation might play an important role in anal fistulas and potentially in their persistence after surgery. Studies on etiology and pathogenesis of anal fistulas are rare, but we suggested that a better understanding of the disease will eventually help in the development of new treatments of anal fistulas. Therefore, in the second part of this thesis, we aimed to gain a better understanding of the pathogenesis of anal fistulas.

## TREATMENT

Classification of anal fistulas is based on the course of the fistula tract in relation to the anal sphincters.<sup>12</sup> Of the four main types of fistulas, the transsphincteric fistula is the second most common one. Transsphincteric fistulas are classified as high or low. For many surgeons this classification is useful for selecting the optimal treatment and supporting the choice between non-sphincter preserving procedures, such as fistulotomy, and sphincter preserving techniques, such as TAFR and LIFT. Although the distinction between high and low transsphincteric fistulas is commonly practiced,

it is unknown whether these fistulas have similar characteristics or not. In Chapter 2 differences between high and low transsphincteric fistulas were evaluated. The study showed that low transsphincteric fistulas occurred more frequently at a younger age (42 vs. 47 years) and more often in females (43% vs. 30% in high transsphincteric fistulas). These fistulas were predominantly anterior (76% vs. 18% in high transsphincteric fistulas) and were rarely associated with an abscess (4% vs. 54% in high transsphincteric fistulas). The internal opening of high transsphincteric fistulas was predominantly located in the posterior midline. Differences in location of internal fistula opening and gender are difficult to explain as there is no gender-specific distribution of anal glands.<sup>13</sup> However, we suggest that some of the low transsphincteric fistulas observed in females may be secondary to episiotomy and this may explain the difference in gender and age. The result of this study may have implications for clinical practice. In patients with a low transsphincteric fistula, fistulotomy is still advocated as the treatment of choice with a minimal risk of incontinence. There is growing evidence, however, that fecal continence is yet at risk following division of the lower third of the external anal sphincter, especially in females with an anterior fistula.<sup>14,15</sup> Female patients are probably at risk because they have a shorter external anal sphincter, which is prone to damage during childbirth.<sup>16,17</sup> In the study described in Chapter 2 almost half the patients with a low transsphincteric fistula were female. In these patients sphincter preserving techniques such as LIFT may be preferable to conventional fistulotomy.

Fistulotomy is not suitable for patients with a high transsphincteric fistula and TAFR has been advocated as the treatment of choice for these anal fistulas. Initially, reported healing rates after TAFR varied between 84% and 100%.<sup>18-21</sup> However, it has become clear that TAFR fails in one of every three patients.<sup>2-6</sup> It has been reported that smoking, obesity and previous attempts at repair adversely affect the outcome of TAFR.<sup>4,6,22,23</sup> Because these findings could not be confirmed by other studies, it is still unclear whether these and other factors have an impact on the outcome of TAFR.<sup>4,5,23-25</sup> In Chapter 3 seventeen potential predictors of outcome were assessed in 252 patients with a high transsphincteric fistula who underwent TAFR. The study showed that the outcome after TAFR is significantly better in patients with horseshoe extension. An explanation for this unexpected finding might be the possibility that the course of the fistula depends on the severity of the fistulous disease. The more fulminant the fistulous disease, the more perpendicular the fistula might traverse through the anal sphincters, resulting in a direct course to the external fistula opening.

In a previous study performed at our institution, the outcome of repeat TAFR was examined in 26 patients, who experienced a failure after the initial procedure. In all of these patients complete healing of the flap was noticed, except at the site of the original internal opening.<sup>26</sup> This remarkable clinical finding raised the question whether



ongoing disease in the remaining tract contributes to persistence of the fistula after flap repair. Most of the remaining tract is located in the intersphincteric plane near the origin of the fistula. LIFT was introduced as an attractive sphincter-preserving alternative by Rojanasakul and he observed 94% primary fistula healing.<sup>27</sup> Based on these promising results, we suggested that this procedure could be useful for eradication of the ongoing disease in the remaining fistula tract, thereby improving the outcome of TAFR. In Chapter 4 the effect of an additional LIFT on the outcome of TAFR in patients with a high transsphincteric fistula was evaluated. Primary healing was observed in 51%. Of the 49% with a failure, the original transsphincteric fistula persisted in 29%. In 20%, the transsphincteric fistula was converted into an intersphincteric fistula. These patients underwent subsequent fistulectomy, which was successful in all of them. The overall healing rate was 71%. In conclusion, an additional LIFT does not improve the outcome of TAFR.

Fistulotomy is considered the treatment of choice for patients with a low transsphincteric fistula. However, there is growing evidence that the risk of diminished fecal continence following fistulotomy is significant, especially in female patients with an anterior fistula and patients with diminished anal sphincter function.<sup>14,15</sup> LIFT is a sphincter preserving procedure that may also be applied in low transsphincteric fistulas. In Chapter 5 the clinical results of LIFT in patients with a low transsphincteric fistula were described. Primary healing was observed in 82%. In patients without primary healing, the transsphincteric fistula was converted into an intersphincteric fistula. This phenomenon suggests that LIFT is sufficient on the side of the external anal sphincter but not always on the side of the internal anal sphincter, resulting in ongoing inflammation in the intersphincteric plane. In Chapter 7 we revealed that the intersphincteric fistula tract of most anal fistulas is lined with granulation tissue. The presence of granulation tissue may be suggestive of an inflammatory process. Conversion to an intersphincteric fistula due to ongoing intersphincteric disease requires a second procedure, fistulotomy, including division of the lower part of the internal anal sphincter. This could be considered a disadvantage of the LIFT technique, with a potential risk of continence disturbance. Other studies have reported diminished fecal continence in up to 38% of the patients that underwent fistulotomy for an intersphincteric fistula. In this study the median Rockwood Fecal Incontinence Severity Index (RFISI) was not changed. We suggest that LIFT is a good alternative for fistulotomy. However, in some patients a second procedure is needed.

In Chapter 6, we evaluated TAFR combined with drainage of associated abscesses in high intersphincteric fistulas in a series of 14 patients. Intersphincteric fistulas with a high upward extension, up to or above the level of the puborectal muscle, in the intersphincteric plane are rare.<sup>12</sup> Most of these fistulas have no external opening and they are frequently associated with a high intersphincteric and/or supralelevator abscess.

Division of a large amount of internal anal sphincter by extended fistulotomy has a potential risk of diminished fecal continence. To our knowledge no reports are available regarding sphincter preserving alternatives for the treatment of these fistulas. In this study TAFR with adequate drainage of the abscesses was successful in 79%, except in patients with supralelevator extension. In these patients additional procedures (including adequate drainage with or without TAFR) were needed to achieve healing. Since preoperative endoanal MRI revealed associated abscesses in 13 patients, we advise appropriate preoperative imaging for all high intersphincteric fistulas. This provides essential information and guides the surgical procedure, especially regarding the approach of associated abscesses and the identification of intersphincteric horseshoe extension.

## PATHOGENESIS

Epithelialization is considered a major cause for persistence of anal fistulas. Lunniss et al. observed epithelium lining in the majority of anal fistulas and van Koperen et al. observed epithelium lining predominantly near the internal fistula opening. Although the effect of this epithelialization on fistula healing was not assessed, both studies stated that this might be a cause for the persistence of the fistula.<sup>28,29</sup> In Chapter 7, we assessed the prevalence of epithelialization of the fistula tract and its effect on the outcome of fistula surgery. We observed epithelialization in only 25% and granulation tissue in 75% of the fistula tracts. There was no difference in outcome between fistulas with or without epithelialization. It has been suggested that perpetuation of inflammation prevents the migration and arrangement of myofibroblasts, which are the key cells in the tissue repair process.<sup>30</sup> These cells are able to form a new basement membrane, which is a prerequisite for the migration of epithelial cells. The lack of epithelialization and presence of granulation tissue in the majority of the fistula tracts may be an expression of ongoing inflammatory process.

Some authors studied the bacteriology of anal fistulas.<sup>31-33</sup> Their reports failed to demonstrate pathogenic bacteria. Moreover, only low numbers of organisms were found, suggesting that permanent infection is not a major contributing factor to the persistence of perianal fistulas. Since these data were obtained only with the use of conventional microbiological culture techniques and live bacteria as well as inflammatory bacterial remnants could potentially contribute to the ongoing inflammation in the remaining fistula tract, we assessed bacteria in the fistula tract by means of conventional microbiological culture and 16S rRNA gene sequencing, and we assessed pro-inflammatory bacterial peptidoglycan (PG) by immunohistochemistry in Chapter 8. Studies on the pathogenesis of different chronic inflammatory diseases, such as

Crohn's disease, show that PG is a powerful effector stimulating inflammation.<sup>34,35</sup> A paucity of bacteria was observed in the fistula tracts. Bacterial species were bowel derived, skin derived, or a combination of both. Therefore, it seems unlikely that bacterial infection plays a major role in persistence of fistula after surgery. These results were recently confirmed by Tozer et al.<sup>36</sup> In contrast, we detected pro-inflammatory PG in the majority of anal fistulas. PG has potent pro-inflammatory properties and stimulates processing and secretion of the cytokine interleukin (IL)-1 $\beta$ . This suggests that even in the absence of local bacterial replication, bacterial components promote chronic inflammation.

Cytokines, such as IL-1 $\beta$ , play an important role in inflammation. At present, many biologicals targeting cytokines or their receptors are available for treatment of a wide array of inflammatory diseases. Therefore, detection and identification of cytokines in anal fistulas might have implications for future treatment modalities. We assessed the local production of a selected panel of cytokines in anal fistulas, including pro-inflammatory IL-1 $\beta$  and tumor necrosis factor  $\alpha$  (TNF- $\alpha$ ). The results are described in Chapter 9. The key finding of this study was the abundant expression of IL-1 $\beta$  in 93% of the anal fistulas. Also, cytokines IL-8, IL-12p40 and TNF- $\alpha$  were present in respectively 70%, 33% and 30% of the anal fistulas. We propose that adjunct treatment of anal fistulas by targeting cytokines may potentially be beneficial. Further research on this matter is warranted.

## FUTURE PERSPECTIVES

The objective of modern anal fistula treatment is healing of the fistula without diminished fecal continence. Sphincter saving techniques have been developed for anal fistulas, for which fistulotomy is not suitable. Treatment of these anal fistulas remains challenging and to some extent disappointing. Despite our effort it seems unlikely that surgical treatment alone will ever lead to fistula healing in all patients. We suggest that inflammation plays a role. In Chapter 9, we observed the abundant expression of pro-inflammatory cytokine IL-1 $\beta$  in the majority of anal fistulas. Cytokines play an important role in inflammation and elevated levels of IL-1 $\beta$  are observed in diseases, such as hidradenitis suppurativa. Currently, three IL-1 antagonists targeting IL-1 $\beta$  are approved for treatment of various diseases and new indications are on their way. Treatment of anal fistulas may need a new approach, combining surgery with treatment of inflammation. Proposals for future research and treatment:

- Research on random treatment options for anal fistulas should stop. We first have to understand the disease before we can treat it.

- Future research should focus on etiology and pathogenesis of anal fistulas. This is highly underrated in the current literature. Furthermore, this may provide targets for additional treatment.
- Sphincter preserving procedures alone do not enable the healing of all anal fistulas. It seems likely that these procedures should be combined with additional treatment of inflammation within the fistula tract to improve the outcome. Further studies on this matter are necessary.

## REFERENCES

1. Ellis CN. Sphincter-preserving fistula management: what patients want. *Dis Colon Rectum*. 2010;53:1652-1655.
2. Lunniss PJ, Kamm MA, Phillips RK. Factors affecting continence after surgery for anal fistula. *Br J Surg*. 1994;81:1382-1385.
3. Mitalas LE, Gosselink MP, Oom DM, et al. Required length of follow-up after transanal advancement flap repair of high transsphincteric fistulas. *Colorectal Dis*. 2008;11:726-728.
4. Zimmerman DD, Delemarre JB, Gosselink MP, et al. Smoking affects the outcome of transanal mucosal advancement flap repair of transsphincteric fistulas. *Br J Surg*. 2003;90:351-354.
5. Mizrahi N, Wexner SD, Zmora O, et al. Endorectal advancement flap: are there predictors of failure? *Dis Colon Rectum*. 2002;45:1616-1621.
6. Schouten WR, Zimmerman DD, Briel JW. Transanal advancement flap repair of transsphincteric fistulas. *Dis Colon Rectum*. 1999;42:1419-1422.
7. Shanwani A, Azmi M, Amri N. The ligation of intersphincteric fistula tract (LIFT) for fistula-in-ano: sphincter saving technique. *Dis Colon Rectum*. 2010;53:39-42.
8. Tan K, Tan IJ, Lim FS, et al. The anatomy of failures following the ligation of intersphincteric fistula tract technique for anal fistula: a review of 93 patients over 4 years. *Dis Colon Rectum*. 2011;54:1368-1372.
9. Bleier H, Moloo H, Goldberg S. Ligation of the intersphincteric fistula tract (LIFT): an effective new technique for complex fistulas. *Dis Colon Rectum*. 2010;53:43-46.
10. Aboulian A, Kaji AH, Kumar RR. Early results of ligation of the intersphincteric fistula tract for fistula-in-ano. *Dis Colon Rectum*. 2011;54:289-292.
11. Ooi K, Skinner I, Croxford M, et al. Managing fistula-in-ano with ligation of the intersphincteric fistula tract procedure: the Western Hospital experience. *Colorectal Dis*. 2011;14:599-603.
12. Parks AG, Gordon PH, Hardcastle JD. A classification of fistula-in-ano. *Br J Surg*. 1976;63:1-12.
13. McColl I. The comparative anatomy and pathology of anal glands. *Ann R Coll Surg Engl*. 1967;40:36-67.
14. Van Tets WF, Kuijpers HC. Continence disorders after anal fistulotomy. *Dis Colon Rectum*. 1994;37:1194-1197.
15. Garcia-Aguilar J, Belmonte C, Wong WD, et al. Anal fistula surgery. Factors associated with recurrence and incontinence. *Dis Colon Rectum*. 1996;39:723-729.
16. Sultan AH, Michael CB, Kamm A, et al. Anal-sphincter disruption during vaginal delivery. *New Engl J Med*. 1993;329:1905-1911.
17. Fitzpatrick M, Fynes M, Cassidy M, et al. Prospective study of the influence of parity and operative technique on the outcome of primary anal sphincter repair following obstetrical injury. *Eur J Obstet Gynecol Reprod Biol*. 2000;89:159-163.
18. Wedell J, Meier zu Eissen P, Banzhaf G, et al. Sliding flap advancement for the treatment of high level fistulae. *Br J Surg*. 1987;74:390-391.
19. Oh C. Management of high recurrent anal fistula. *Surgery*. 1983;93:330-332.
20. Kodner IJ, Mazor A, Shemesh EI, et al. Endorectal advancement flap repair of rectovaginal and other complicated anorectal fistulas. *Surgery*. 1993;114:682-689.
21. Aguilar PS, Plasencia G, Hardy TG Jr, et al. Mucosal advancement in the treatment of anal fistula. *Dis Colon Rectum*. 1985;28:496-498.
22. Ellis CN, Clark S. Effect of tobacco smoking on advancement flap repair of complex anal fistulas. *Dis Colon Rectum*. 2007;50:459-463.

23. Schwandner O. Obesity is a negative predictor of success after surgery for complex anal fistula. *BMC Gastroenterology*. 2011;11:61.
24. Van Koperen PJ, Wind J, Bemelman WA, et al. Long-term functional outcome and risk factors for recurrence after surgical treatment for low and high perianal fistulas of cryptoglandular origin. *Dis Colon Rectum*. 2008;51:1475-1481.
25. Uribe N, Millán M, Minguez M, et al. Clinical and manometric results of endorectal advancement flaps for complex anal fistula. *Int J Colorectal Dis*. 2007;22:259-264.
26. Mitalas LE, Gosselink MP, Zimmerman DD, et al. Repeat transanal advancement flap repair: impact on the overall healing rate of high transsphincteric fistulas and on fecal continence. *Dis Colon Rectum*. 2007;50:1508-1511.
27. Rojanasakul A. LIFT procedure: a simplified technique for fistula-in-ano. *Tech Coloproctol*. 2009;13:237-240.
28. Lunniss PJ, Sheffield JP, Talbot IC, et al. Persistence of idiopathic anal fistula may be related to epithelialization. *Br J Surg*. 1995;82:32-33.
29. Van Koperen PJ, Ten Kate FJW, Bemelman WA, et al. Histological identification of epithelium in perianal fistulae: a prospective study. *Colorectal Dis*. 2010;12:891-895.
30. Bataille F, Rohrmeier C, Bates R, et al. Evidence for a role of epithelial mesenchymal transition during pathogenesis of fistulae in Crohn's disease. *Inflamm Bowel Dis*. 2008;14:1514-1527.
31. de San Ildefonso Pereira A, Maruri Chimeno I, Facal Alvarez C, et al. Bacteriology of anal fistulae. *Rev Esp Enferm Dig*. 2002;94:533-536.
32. Lunniss PJ, Faris B, Rees HC, et al. Histological and microbiological assessment of the role of microorganisms in chronic anal fistula. *Br J Surg*. 1993;80:1072.
33. Seow-Choen F, Hay AJ, Heard S, et al. Bacteriology of anal fistulae. *Br J Surg*. 1992;79:27-28.
34. Inohara N, Ogura Y, Fontalba, et al. Host recognition of bacterial muramyl dipeptide mediated through NOD2. Implications for Crohn's disease. *J Biol Chem* 2003;278:5509-5512.
35. Laman JD, Schoneveld AH, Moll FL, et al. Significance of peptidoglycan, a proinflammatory bacterial antigen in atherosclerotic arteries and its association with vulnerable plaques. *Am J Cardiol* 2002;90:119-123.
36. Tozer PJ, Rayment N, Hart AL, et al. What role do bacteria play in persisting fistula formation in idiopathic and Crohn's anal fistula? *Colorectal Dis* 2015;17:235-241.







Chapter 11

**Summary in Dutch  
(Nederlandse samenvatting)**



Anale fistels worden behandeld sinds het begin van de geneeskunde. De klassieke behandeling van anale fistels is de fistel chirurgisch open te leggen (fistulotomie). Hoewel dit een erg effectieve behandeling is, bestaat er een risico op verminderde fecale continëntie bij patiënten met een anale fistel die hoog door de anale kringsspieren loopt.

In de moderne colorectale chirurgie is behalve genezing ook behoudt van fecale continëntie belangrijk. Recent onderzoek toont namelijk dat voor de meeste patiënten een laag risico op fecale incontinentie belangrijker is dan hoge kans op genezing. Over de tijd zijn er verscheidenen kringspier sparende operaties ontwikkeld voor anale fistels, zoals de transanale mucosa verschuivingsplastiek (TAMVP) en ligatie van het intersfincterische fistel traject (LIFT). Hoewel deze kringspier sparende operaties effectief zijn in het voorkomen van verminderde fecale continëntie na de operatie, leiden ze minder vaak tot genezing dan een fistulotomie. De genezing na een TAMVP varieert tussen 60 en 70% en het genezingspercentage na een LIFT varieert tussen 50 en 70%. De reden voor deze teleurstellende resultaten is onduidelijk en voorspellers voor de uitkomst van de operaties zijn tot op heden niet duidelijk geïdentificeerd.

In het proefschrift hebben we eerst de toepassing van verschillende kringspier sparende operaties onderzocht en geprobeerd voorspellers voor de uitkomst van de operaties te identificeren. Anale fistels worden namelijk beschouwd als een chirurgische uitdaging en de meeste studies naar anale fistels zijn uitgevoerd om de chirurgische behandeling te optimaliseren door nieuwe operatie technieken te ontwikkelen en evalueren. Ondanks onze pogingen bleven de genezingspercentages teleurstellend en leek het onwaarschijnlijk dat chirurgische behandeling ooit zal leiden tot genezing in alle patiënten. Hierop hebben we besloten onze benadering aan te passen. We stelden namelijk voor dat een persisterende ontsteking mogelijk een belangrijke rol zou kunnen spelen in het recidiveren van anale fistels na de operatie en dat een beter begrip van de ziekte uiteindelijk zal helpen bij het ontwikkelen van nieuwe en hopelijk succesvollere behandelingen. Daarom is het tweede deel van het proefschrift gericht op het beter begrijpen van de pathogenese van anale fistels.

## BEHANDELING

De indeling van anale fistels is gebaseerd op het verloop van de fistel ten opzichte van de anale kringsspieren. Van de vier algemene type anale fistels is de transsfincterische fistel de tweede meest voorkomende fistel. Transsfincterische fistels kunnen worden geclassificeerd als hoog of laag. Voor veel chirurgen is deze classificatie handig voor het selecteren van de optimale behandeling en de keuze tussen een niet kringspier sparende operatie (fistulotomie) en een kringspier sparende operatie (TAMVP en LIFT).

Hoewel het onderscheidt tussen hoge en lage transsfincterische fistels algemeen wordt toegepast, is het onbekend of deze fistels verschillende kenmerken hebben. In Hoofdstuk 2 zijn de verschillen tussen hoge en lage transsfincterische fistels onderzocht. De studie toonde dat lage transsfincterische fistels vaker voorkomen op jongere leeftijd (42 versus 47 jaar) en bij vrouwen (43% versus 30%). Verder zijn lage transsfincterische fistels overwegend anterieur gelokaliseerd (76 versus 18%) en zelden geassocieerd met een abces (4 versus 54%). De interne fistelopening van hoge transsfincterische fistels was voornamelijk gelokaliseerd midden posterieur. Het verschil in locatie van de interne fistel opening en het geslacht is moeilijk te verklaren omdat er geen geslacht specifieke verdeling is van anale klieren. Echter, veronderstellen we dat sommige van de lage transsfincterische fistels die bij vrouwen zijn waargenomen mogelijk secundair zijn aan een episiotomie. Dit zou mogelijk het verschil in leeftijd en geslacht kunnen verklaren. De resultaten van het onderzoek zouden gevolgen kunnen hebben voor de kliniek. Bij patiënten met een lage transsfincterische fistel is namelijk fistulotomie de behandeling van keuze. Echter is er steeds meer bewijs dat het risico op verminderde fecale continëntie na fistulotomie veel groter is dan aanvankelijk werd aangenomen en in het bijzonder bij vrouwen met een anterieure fistel. Het risico bij vrouwen is waarschijnlijk groter, omdat ze een kortere uitwendige kringspier hebben die kan beschadigen bij vaginale bevalling. In de studie beschreven in Hoofdstuk 2 zijn bijna de helft van de patiënten met een lage transsfincterische fistel vrouw. Voor deze patiënten zou een kringspier sparende operatie, zoals LIFT, mogelijk een betere behandeling zijn dan een conventionele fistulotomie.

Fistulotomie is niet geschikt voor patiënten met een hoge transsfincterische fistel en TAMVP wordt beschouwd als de behandeling van keuze voor dit type fistel. Aanvankelijk varieerde de gerapporteerde genezingspercentages na TAMVP tussen 84% en 100%. Echter is duidelijk geworden dat TAMVP onsuccesvol is in één van de drie patiënten. Enkele studies toonde aan dat roken, obesitas en eerdere operaties de uitkomst van TAMVP nadelig beïnvloeden, echter werden deze bevindingen nooit bevestigd door andere studies. Hierdoor is er nog veel onduidelijkheid welke factoren mogelijk invloed hebben op de uitkomst van TAMVP. In Hoofdstuk 3 worden zeventien potentiële voorspellers van de uitkomsten van TAMVP onderzocht bij 252 patiënten met een hoog transsfincterische fistel. De studie toonde aan dat patiënten met een hoefijzervormige extensie van de fistel een aanzienlijk betere uitkomst hadden van de behandeling. Een mogelijke verklaring voor deze onverwachte bevinding is dat het traject van de fistel afhankelijk is van de ernst van de ziekte. Hoe ernstiger de fistuleuze ziekte, hoe directer de fistel de kringspijeren doorkruist. Fistels zonder hoefijzervormige extensie zijn daarom lastiger te behandelen.

In eerdere studie van onze onderzoeksgroep werd het effect van een tweede TAMVP onderzocht. Tijdens de tweede TAMVP werd vastgesteld dat na de eerst ingreep de

flap overall was ingegroeid, behalve op de plaats van de oorspronkelijke inwendige opening. Deze opmerkelijke klinische bevinding suggereert dat het persisteren van de fistel na TAMVP veroorzaakt zou kunnen worden door het voortduren van het ziekteproces in het resterende fistelkanaal. Het resterende fistelkanaal na TAMVP is gelegen in de intersfincterische ruimte vlakbij de oorsprong van de fistel. LIFT werd geïntroduceerd als een aantrekkelijke kringspier sparende operatie door Rojanasakul, die een genezingspercentage van 94% beschreef. Op basis van deze veelbelovende resultaten suggereerden wij dat LIFT mogelijk het voortdurende ziekteproces in het resterende fistelkanaal kan verwijderen en hierdoor de resultaten van TAMVP zou verbeteren. In Hoofdstuk 4 wordt het effect van een additionele LIFT geëvalueerd op de uitkomst van TAMVP bij patiënten met een hoge transsfincterische fistel. Primaire genezing werd geobserveerd in 51% van de patiënten. In 29% van de patiënten recidiveerde de hoge transsfincterische fistel. In 20% van de patiënten werd een conversie geobserveerd, van transsfincterische fistel naar intersfincterische fistel. Daaropvolgend ondergingen deze patiënten een fistulectomie, waarbij de inwendige kringspier werd gekliefd. In alle patiënten was deze ingreep succesvol, waardoor de totale genezing in de studie 71% bedroeg. We concludeerden dat een additionele LIFT de uitkomst van TAMVP niet verbeterd.

Fistulotomie wordt beschouwd als de behandeling van keuze voor patiënten met een lage transsfincterische fistel. Echter zijn er steeds meer aanwijzingen dat het risico op verminderde fecale continëntie na fistulotomie aanzienlijk is. Vooral vrouwelijke patiënten met een anterieure fistel en patiënten met een verminderde kringspier functie lopen een groter risico. LIFT werd initieel toegepast bij hoge transsfincterische fistels, echter zou deze kringspier sparende procedure ook kunnen worden ingezet bij lage transsfincterische fistels. Hoofdstuk 5 beschrijft de klinische resultaten van LIFT bij patiënt met een lage transsfincterische fistel. Primaire genezing werd geobserveerd in 82% van de patiënten. In alle patiënten zonder primaire genezing werd een conversie van lage transsfincterische fistel naar lage intersfincterische fistel waargenomen. Dit verschijnsel doet vermoeden dat LIFT voldoende genezing biedt aan de kant van de uitwendige kringspier maar niet altijd voldoende genezing biedt aan de kant van de inwendige kringspier en hierdoor leidt tot een aanhoudende ontsteking in het intersfincterische vlak. In Hoofdstuk 7 toonde we aan dat het intersfincterische fisteltraject in de meeste gevallen bekleed is met granulatie weefsel. De aanwezigheid van granulatie weefsel is suggestief voor een inflammatoir proces. Conversie naar een intersfincterische fistel zou het gevolg kunnen zijn van een aanhoudend inflammatoire proces. Door conversie was een tweede ingreep noodzakelijk, waarbij een fistulotomie werd uitgevoerd. Dit kan worden beschouwd als een nadeel van de LIFT techniek, met een potentieel risico op verminderde fecale continëntie. Enkele studies toonde verminderde fecale continëntie bij 38% van de patiënten. In de huidige studie

was de mediane Rockwood Fecale incontinentie Severity Index (RFISI) onveranderd na operatie. Wij stellen voor dat LIFT is een goed alternatief voor fistulotomie, echter bij sommige patiënten zal een tweede procedure noodzakelijk zijn.

Hoofdstuk 6 beschrijft de resultaten van TAMVP gecombineerd met drainage van abscessen bij een serie van 14 patiënten met een hoge intersfincterische fistel. Intersfincterische fistels met een hoog opwaarts verloop, tot aan of boven het niveau van de puborectale spieren, zijn zeldzaam. De meeste van deze fistels hebben geen uitwendige opening en worden vaak geassocieerd met een hoge intersfincterische en/of supraleatoire abscessen. Het klieven van een groot deel van de inwendige kringspier bij een verlengde fistulotomie leidt tot een potentieel risico op verminderde fecale continentie. Voor zover bekend zijn er geen studies over kringspier sparende behandelingen van deze fistels. In de huidige studie was TAMVP met drainage van de abscessen succesvol in 79% van de patiënten. Alleen bij patiënten met een supraleutoir abces werd geen primaire genezing geobserveerd en waren aanvullende procedures (inclusief drainage met of zonder TAMVP) noodzakelijk om genezing te bereiken. Aangezien endoanale MRI bij 13 patiënten abscessen toonde, adviseren wij preoperatieve beeldvorming voor alle hoge intersfincterische fistels. Dit levert namelijk essentiële informatie voor de chirurgische ingreep.

## PATHOGENESE

Epithelialisatie wordt beschouwd als een belangrijke oorzaak voor het persisteren van anale fistels. Lunniss et al. observeerden epithelialisatie in de meerderheid van de fistels en van Koperen et al. vonden voornamelijk epithelialisatie vlakbij de interne fistel opening. Hoewel het effect van epithelialisatie nooit werd onderzocht, suggereerde beide studies dat dit mogelijk de oorzaak was voor het persisteren van anale fistels. Hoofdstuk 7 beschrijft de prevalentie van epithelialisatie in het anale fisteltraject en het effect van epithelialisatie op de uitkomst van fistel chirurgie. Epithelialisatie werd slechts in 25% van de fisteltrajecten waargenomen en in 75% van de fisteltrajecten werd granulatie weefsel aangetoond. Er was geen verschil in uitkomst van fistel chirurgie tussen fistels met of zonder epithelialisatie. Er wordt gesuggereerd dat persistente inflammatie voorkomt dat myofibroblasten kunnen migreren. Myofibroblasten spelen een belangrijke rol in het weefsel herstel proces. Deze cellen zijn in staat om een nieuw basaal membraan te vormen, wat een voorwaarde is voor de migratie van epitheliale cellen. De afwezigheid van epithelialisatie en aanwezigheid van granulatie weefsel in het merendeel van de fisteltrajecten zou een uiting kunnen zijn van een persistente inflammatie.

Verscheidende auteurs beschreven de bacteriologie van anale fistels. Zij toonde aan dat er geen sprake was van pathogene bacteriën. Bovendien was er slechts sprake van een laag aantal bacteriën, dit suggereert dat permanente infectie geen belangrijke bijdragen zou hebben bij het persisteren van fistels. De auteurs paste alleen conventionele microbiologische kweektechnieken toe, echter kunnen behalve levende bacteriën ook bacteriële resten bijdragen tot een persistente ontsteking in het resterende fisteltraject. In Hoofdstuk 8 werden conventionele microbiologische kweektechnieken en 16S rRNA gene sequencing toegepast voor het observeren van bacteriën en immunohistochemie werd toegepast voor het aantonen van pro-inflammatoire bacteriële peptidoglycanen (PG). Studies naar de pathogenese van verschillende chronische ontstekingsziekten, zoals de ziekte van Crohn, tonen aan dat PG een krachtige stimulator is voor ontsteking. Uit onze studie bleek dat fistels niet gekoloniseerd waren met pathogene bacteriën en het aantal aanwezige bacteriën zeer klein was. Daarom lijkt het onwaarschijnlijk dat een bacteriële infectie een belangrijke rol speelt bij het persisteren van fistels. Deze resultaten werden onlangs bevestigd door Tozer et al.. In tegenstelling tot de bevindingen van conventionele microbiologische kweektechnieken en 16S rRNA gene sequencing, observeerden we wel pro-inflammatoire PG in de meeste fistels. PG heeft krachtige pro-inflammatoire eigenschappen en stimuleert de verwerking en secretie van cytokine interleukine (IL)-1 $\beta$ . Dit suggereert dat zelfs in afwezigheid van lokale bacteriële replicatie, bacteriële resten ontsteking kunnen bevorderen.

Cytokinen, zoals IL-1 $\beta$ , spelen een belangrijke rol bij ontsteking. Veel biologicals, gericht op cytokinen en hun receptoren, zijn beschikbaar voor de behandeling van een breed scala van inflammatoire ziekten. Detectie en identificatie van cytokinen in anale fistels kunnen daarom implicaties hebben voor toekomstige behandelingen. Om deze reden hebben we de aanwezigheid van een geselecteerd panel van cytokinen, zoals pro-inflammatoire IL-1 $\beta$  en tumornecrosefactor  $\alpha$  (TNF- $\alpha$ ), onderzocht in anale fistels. De resultaten zijn beschreven in Hoofdstuk 9. De belangrijkste bevinding van deze studie was de overvloedige expressie van IL-1 $\beta$  in 93% van de anale fistels. Ook cytokinen IL-8, IL-12p40 en TNF- $\alpha$  waren aanwezig in respectievelijk 70%, 33% en 30% van de fistels. We suggereren dat additionele behandeling van anale fistels gericht op cytokinen mogelijk gunstig kan zijn en stellen voor dat dit verder onderzocht moeten worden.

## TOEKOMSTPERSPECTIEVEN

Het doel van moderne anale fistel behandelingen is genezing van de fistel zonder verminderde fecale continëntie. Kringspier sparende behandelingen zijn ontwikkeld

voor anale fistels, waarvoor fistulotomie ongewenst is. Behandeling van deze typen fistels blijft moeilijk en enigszins teleurstellend. Ondanks onze inspanningen lijkt het er namelijk op dat chirurgische behandeling op zichzelf nooit zal leiden tot volledige genezing van alle fistels. We suggereren dat inflammatie een rol speelt. In Hoofdstuk 9 observeerden we de overvloedige expressie van het pro-inflammatoire cytokine IL-1 $\beta$ . Cytokinen spelen een belangrijke rol bij ontsteking en verhoogde expressie van IL-1 $\beta$  wordt waargenomen bij ziekten, zoals hidradenitis suppurativa. Momenteel zijn er drie IL-1 antagonisten gericht op IL-1 $\beta$  goedgekeurd voor de behandeling van diverse ziekten en onderzoek naar nieuwe toepassingen vindt plaats. De behandeling van anale fistels zal mogelijk veranderen, waarbij chirurgie wordt gecombineerd met de behandeling van ontsteking. Voorstellen voor toekomstig onderzoek en behandeling:

- Onderzoek naar willekeurige behandelingsopties voor anale fistels moet stoppen. We zullen eerst de ziekte moeten begrijpen voordat we het kunnen behandelen.
- Toekomstig onderzoek moet zich meer richten op de etiologie en pathogenese van anale fistels. De huidige literatuur hierover is namelijk beperkt. Bovendien zou dit kunnen leiden tot nieuwe (additionele) behandelingsopties.
- Kringspier sparende operaties zullen op zichzelf nooit leiden tot volledige genezing van alle anale fistels. Waarschijnlijk zullen deze procedures gecombineerd moeten worden met additionele behandeling van de inflammatie in de fistel om de genezingskans te verbeteren. Dit behoeft nader onderzoek.







Chapter 12

**Acknowledgments  
(Dankwoord)**

**About the author**

**List of publications**

**PhD portfolio**



## ACKNOWLEDGMENTS (DANKWOORD)

Onderzoek en uiteindelijk de totstandkoming van een proefschrift doe je niet alleen. Het verschijnen van dit proefschrift biedt mij de gelegenheid om allen te bedanken en enkele personen in het bijzonder te noemen.

Allereerst mijn promotor, prof. dr. J.D. Laman, en copromotor dr. W.R. Schouten.

Beste Jon, ik kan me geen betere en fijnere supervisor voorstellen. Je was altijd bereikbaar om te discussiëren over onderzoek en hebt hiermee een grote bijdrage geleverd aan mijn wetenschappelijke vorming. Chirurgie en immunologie liggen op het eerste gezicht ver van elkaar vandaan, maar dit proefschrift laat zien er mooie dingen gebeuren als mensen uit verschillende vakgebieden samenwerken. Zonder jou was dit proefschrift niet geworden wat het nu is en hier ben ik je enorm dankbaar voor.

Beste Ruud, graag wil ik je bedanken voor de mooie periode waarin je mijn onderzoek hebt begeleid. Ik heb veel geleerd van jouw analytische en kritische blik. In je overvolle agenda wist je altijd tijd te vinden om samen te denken en te schrijven aan artikelen en presentaties. Dit waardeer ik geweldig. Het jaarlijkse 'familie etentje' tijdens de ESCP met oud promovendi is een ware traditie geworden en laat volgens mij zien hoe goed jouw band is met je onderzoekers. Ik hoop er nog vele jaren bij te zijn, maar de sardines laten we voortaan achterwegen.

Prof.dr. C.G.M.I. Baeten, prof.dr. E.P. Prens en prof.dr. C.J. van der Woude wil ik graag bedanken voor hun bereidheid zitting te nemen in de kleine promotiecommissie en het beoordelen van mijn proefschrift.

Prof.dr. L.P.S. Stassen en dr. B.P.L. Wijnhoven wil ik bedanken voor hun bereidheid zitting te nemen in mijn promotiecommissie.

Beste David en Litza, ik was jullie opvolger dus zoals jullie begrijpen legt dat nogal wat gewicht op de schouders. Ik heb veel van jullie geleerd en ik wil jullie bedanken voor jullie vriendschap en gezellige tijden.

Dr. K. Monkhorst, prof.dr. A. van Belkum en dr. J. van Rosmalen wil ik graag bedanken voor hun inzet, betrokkenheid en kritiek bij de verschillende publicaties.

Marjan en Marie-Jose, bedankt voor jullie tijd om mij wegwijs te maken op het immunologie lab en mij te helpen met alle experimenten. Zonder jullie zou het niet zijn gelukt.

Beste operatie assistenten, anesthesiologie medewerkers en anesthesiologen van het Havenziekenhuis, elke vrijdag op de operatiekamer was een feestje. Ik wil jullie bedanken voor jullie interesse in mijn onderzoek, de sterke verhalen en de vele catheters die moesten worden ingebracht.

Beste Nuis, wat ooit startte als samen colleges volgen tijdens onze Master cursussen leidde tot een vriendschap die ons bracht naar Costa Rica, New York en Johns Hopkins. In mijn periode van onderzoek en daarbuiten heb ik op je kunnen bouwen voor hulp en advies over onderzoek en vrouwen. Bedankt voor de mooie avonturen.

Benno. Ooit waren we voedingsfeuten op de afdeling Interne Geneeskunde maar die tijd is voorbij. Jij bent tegenwoordig psychiater in spe en ik krap met dit proefschrift de 's' van drs. Met een glimlach denk ik terug aan de tijd dat we huisgenoten waren. Ik wil je bedanken voor je sterke bakken koffie en jouw steun door het aanhoren van mijn commentaar in minder goede tijden.

Beste Sjoerd, we kenden elkaar al van de co-groep maar onze samenwerking en vriendschap begon pas in de Witte Aap. Je vertelde me daar dat je keuze onderzoek voortijdig was gestopt en je per direct een nieuwe plek zocht. Aan de bar bood ik je een onderzoek en bier aan en twee dagen later zaten we samen artikelen door te lezen. Tijdens het onderzoek ben je een goede maat van me geworden en ik ben je dankbaar voor de mooie tijd.

Beste Gert Jan, je mag dan geen directe betrokkenheid hebben gehad bij mijn promotie maar je bent zeker betrokken geweest met mijn vorming als homo universalis. Jouw steun en betrokkenheid bij de diverse projecten is uniek. In je overvolle agenda vond je vaak tijd om dingen door te praten en projecten tot een hoger niveau te brengen. Ik wil je graag bedanken voor al je steun.

Beste collega's in het Maasstad Ziekenhuis en Erasmus MC, ik wil jullie bedanken voor de leerzame momenten, maar natuurlijk ook voor de mooie tijden bij de wintersport en vele borrels.

Tjeerd, Jeroen, Renske, Nynke en Niels. We kennen elkaar al sinds het tweede jaar middelbare school. Van hangen op het schoolplein tot nu is er te veel moois gebeurd

om in een dankwoord te passen, maar het is duidelijk dat na al die jaren de band tussen ons ontzettend sterk is. Door diensten en veel werken moest ik onze afspraken soms afzeggen, maar jullie hebben dit altijd geaccepteerd en mij gesteund in mijn keuzes. Ik kan me geen betere vrienden voorstellen en ik ben jullie heel dankbaar voor jullie vriendschap en steun.

Lieve Hanke, we kennen elkaar al jaren en wij waren de eerste uit Alkmaar die naar Rotterdam vertrokken om Geneeskunde te studeren. We hebben elkaar zien groeien van irritante pubers tot artsen en we kennen elkaar daarom door en door. Je bent een fantastisch persoon en vriendin, en staat altijd voor mij klaar. Met jou als paranimf komt de verdediging zeker goed.

Beste Martijn, vanaf het begin van mijn onderzoek was jij er bij en nu voor de afronding sta je naast me als paranimf. Ik heb veel van je geleerd over onderzoek en de kliniek. Vele uren in WP hebben dit proefschrift vormgegeven en nieuwe ideeën voor onderzoek vonden daar hun levenslicht. Want zoals je me ooit in Oxford vertelde, je leert veel van colleges en boeken maar in de kroeg vindt pas de discussie plaats die je echt doet nadenken over een onderwerp. Ik bedank je voor deze mooie tijd en ik verwacht dat onze samenwerking in de toekomst nog meer goede dingen brengt.

Lieve Tahnee, we kennen elkaar al lange tijd maar ik heb je pas beter leren kennen tijdens het laatste deel van dit proefschrift. Je bent degene die alles van dichtbij heeft meegemaakt en mijn goede en slechte kanten heeft gezien. Je hebt me gesteund met lieve woorden, maar wist me ook met beide benen op de grond te zetten als dat nodig was. Ik ben blij dat jij hierbij aan mijn zijde stond en dat we ons kunnen opmaken voor de volgende stap.

Tot slot wil ik mijn familie bedanken. Lieve Zoë. Als broer en zus hebben we vaak aan een half woord genoeg. We staan altijd voor elkaar klaar en je had altijd een luisterend oor als het niet goed ging. Nu het proefschrift afgerond is heb ik eindelijk tijd om weer voor je te koken. Heel veel dank voor al je steun. In het bijzonder wil ik mijn lieve ouders bedanken. Jullie hebben me opgevoed als iemand die de handen uit de mouwen steekt en nooit opgeeft, maar zonder steun, liefde en vertrouwen sta je nergens. Jullie stonden altijd voor me klaar en het mag dan ook duidelijk zijn dat zonder jullie onvoorwaardelijke steun dit proefschrift nooit was afgerond.





## ABOUT THE AUTHOR

Robbert van Onkelen was born on July 16, 1985 in Alkmaar, the Netherlands. After graduating from secondary school, he could not yet pursue his ambitions in medicine for two years. In these years he studied Psychology at the University of Leiden and Architecture at the Technical University of Delft before entering Medical School at the Erasmus University in 2005. In parallel, he obtained a Master of Science in Health Sciences (2012), with sessions at Johns Hopkins University School of Public Health, Baltimore, MD, USA.

At the start of his clinical internships he was introduced to Dr. W.R. Schouten and Prof. Dr. J.D. Laman and started several research projects under their supervision. After completing his medical degree he continued his research in a PhD project, focusing on the treatment and pathogenesis of anal fistulas. In this period he spent a month in Oxford, where he conducted research at the department of colorectal surgery, Oxford University Hospitals, Oxford, United Kingdom.

After a year of fulltime research Robbert started with clinical work at the department of surgery at Maasstad Hospital, Rotterdam, the Netherlands for one and a half years and continued his clinical work at the department of surgery at Erasmus Medical Center, Rotterdam, the Netherlands.



## LIST OF PUBLICATIONS

Tang H, van Onkelen RS, van Walsum T, Hameeteman R, Schaap M, Tori FL, van den Bouwhuijsen QJA, Witteman JCM, van der Lugt A, van Vliet LJ, Niessen WJ. A semi-automatic method for segmentation of the carotid bifurcation and bifurcation angle quantification on black blood MRA. *Medical Image Computing and Computer-Assisted Intervention – MICCAI 2010, Lecture Notes in Computer Science 2010*;6363:97-104.

Tang H, van Walsum T, van Onkelen RS, Hameeteman R, Klein S, Schaap M, Tori FL, van den Bouwhuijsen QJA, Witteman JCM, van der Lugt A, van Vliet LJ, Niessen WJ. Semiautomatic carotid lumen segmentation for quantification of lumen geometry in multispectral MRI. *Medical Image Analysis 2012*;16:1202-1215.

Mitalas LE, van Onkelen RS, Gosselink MP, Zimmerman DDE, Schouten WR. The anal fistula plug as an adjunct to transanal advancement flap repair. *Dis Colon Rectum 2010*;53:1713.

van Onkelen RS, Gosselink MP, Schouten WR. Is it possible to improve the outcome of transanal advancement flap repair for high transsphincteric fistulas by additional ligation of the intersphincteric fistula tract? *Dis Colon Rectum 2012*;55:163-166.

Mitalas LE, van Onkelen RS, Monkhorst K, Zimmerman DDE, Gosselink MP, Schouten WR. Identification of epithelialization in high transsphincteric fistulas. *Tech Coloproctol 2012*;16:113-117.

van Onkelen RS, Mitalas LE, Gosselink MP, van Belkum A, Laman JD, Schouten WR. Assessment of microbiota and peptidoglycan in perianal fistulas. *Diagn Microbiol Infect Dis 2013*;75:50-54.

van Onkelen RS, Gosselink MP, Schouten WR. Ligation of the intersphincteric fistula tract in low transsphincteric fistula: A new technique to avoid fistulotomy. *Colorectal Dis 2013*;15:587-591.

van Onkelen RS, Gosselink MP, Schouten WR. Treatment of anal fistulas with high intersphincteric extension. *Dis Colon Rectum 2013*;56:987-991.

Schouten WR, Gosselink MP, Thijsse S, van Onkelen RS. Intersfincterische ligatie van perianale fistels (Intersphincteric ligation of perianal fistula). *Ned Tijdschr Geneeskd* 2013;157:A6505.

van Onkelen RS, Gosselink MP, Thijsse S, Schouten WR. Predictors of outcome after transanal advancement flap repair for high transsphincteric fistulas. *Dis Colon Rectum* 2014;57:1007-1011.

van Onkelen RS, Gosselink MP, van Rosmalen J, Thijsse S, Schouten WR. Different characteristics of high and low transsphincteric fistulae. *Colorectal Dis* 2014;16:403-492.

Gosselink MP, Joshi H, Adusumilli S, van Onkelen RS, Fourie S, Hompes R, Jones OM, Cunningham C, Lindsey I. Laparoscopic ventral rectopexy for faecal incontinence: Equivalent benefit is seen in internal and external rectal prolapse. *J Gastrointest Surg* 2015;19:558-563.

Selwaness M, van Den Bouwhuijsen Q, van Onkelen RS, Hofman A, Franco OH, van der Lugt A, Wentzel JJ, Vernooij M. Atherosclerotic plaque in the left carotid artery is more vulnerable than on the right. *Stroke* 2014;45:3226-3230.

van Onkelen RS, Gosselink MP, Laman JD, Schouten WR. Inflammation in anal fistula. *Colorectal Dis* 2015;17:643-644.

## PHD PORTFOLIO

Name PhD student: Robbert Sebastiaan van Onkelen  
 Departments: Surgery and Immunology, Erasmus MC, University Medical Center, Rotterdam, the Netherlands  
 Title thesis: Anal fistulas: New perspectives on treatment and pathogenesis  
 Promotor: Prof. Dr. J.D. Laman  
 Supervisor: Dr. W.R. Schouten

### Education

Jun. - Jul. 2009 Annual Graduate Summer Institute of Epidemiology and Biostatistics  
 Johns Hopkins University, Bloomberg School of Public Health, Baltimore, MD, USA

2007 - 2012 MSc Research Master in Health Sciences  
 Netherlands Institute for Health Sciences, Rotterdam, the Netherlands

2005 - 2012 Medicine  
 Erasmus University, Rotterdam, the Netherlands

### Teaching

May 2015 Colon Opleiding  
 Lectures on anal fistulas for nurse practitioners as part of their education.  
 Stichting Colon Opleiding, Rotterdam, the Netherlands

2009 - 2010 Human anatomy tutor  
 Teaching clinical anatomy to medical students and nurses as part of their education.  
 Erasmus University, Rotterdam, the Netherlands

2007 - 2010 Erasmus Anatomy Research Project (EARP)  
 Student head and neck anatomy (2007 - 2008), assistant thorax anatomy (2008 - 2009) and tutor thorax anatomy (2009 - 2010). Assistants and tutors provide hands-on anatomy education by offering students the possibility to dissect preserved human bodies.  
 Erasmus University, Rotterdam, the Netherlands

## Entrepreneurship

- 2013 - Present    4Abstracts  
 Founder and managing director. 4Abstracts is a free e-mail service that provides overviews of abstracts of original articles, trials and reviews.  
[www.4abstracts.com](http://www.4abstracts.com)
- 2012 - 2013      Advanced Student Anesthesiology Project (ASAP)  
 Founder and advisor. ASAP is a project that offers anesthesiology education to medical students.  
 Erasmus University, Rotterdam, the Netherlands
- 2011 - 2013      ErasmusMC Foundation for Financing Education and Clinical Tutoring (EFFECT)  
 Founder and advisor. EFFECT is a foundation that offers financial support for educational projects that enhance medical education at Erasmus University.  
[www.erasmusmc.nl/effect](http://www.erasmusmc.nl/effect)

## Scientific presentations

### *Oral presentations*

- Sept. 2015      European Society of Coloproctology (ESCP), 10th Scientific and Annual Meeting, Dublin, Ireland
- Sept. 2014      ESCP, 9th Scientific and Annual Meeting, Barcelona, Spain
- Sept. 2013      ESCP, 8th Scientific and Annual Meeting, Belgrade, Serbia
- Mar. 2013      Grand Rounds, Oxford University Hospitals, Oxford, United Kingdom
- Sept. 2012      ESCP, 7th Scientific and Annual Meeting, Vienna, Austria
- Nov. 2011      Netherlands Society of Gastroenterology (NVGE), Velthoven, the Netherlands
- Sept. 2011      ESCP, 6th Scientific and Annual Meeting, Copenhagen, Denmark

### *Poster presentations*

- Sept. 2015      ESCP, 10th Scientific and Annual Meeting, Dublin, Ireland
- Sept. 2013      ESCP, 8th Scientific and Annual Meeting, Belgrade, Serbia
- Oct. 2011      Dutch Society of Surgeons (NVVH), Ede, the Netherlands
- Oct. 2011      United European Gastroenterology Week (UEGW), Stockholm, Sweden
- Sept. 2010      ESCP, 5th Scientific and Annual Meeting, Sorrento, Italy
- Mar. 2010      European Congress of Radiology (ECR), Vienna, Austria



